



Australian Government  
Department of Health

# Application Form

## Radionuclide imaging using 99mTc-PYP, 99mTc-HDP or 99mTc-DPD for the diagnosis of transthyretin amyloid cardiomyopathy

**(New and/or Amended Requests for Public Funding)**

**(Version 2.4)**

This application form is to be completed for new and amended requests for public funding (including but not limited to the Medicare Benefits Schedule (MBS)). It describes the detailed information that the Australian Government Department of Health requires in order to determine whether a proposed medical service is suitable.

Please use this template, along with the associated Application Form Guidelines to prepare your application. Please complete all questions that are applicable to the proposed service, providing relevant information only. Applications not completed in full will not be accepted.

Should you require any further assistance, departmental staff are available through the Health Technology Assessment Team (HTA Team) on the contact numbers and email below to discuss the application form, or any other component of the Medical Services Advisory Committee process.

Phone: +61 2 6289 7550

Fax: +61 2 6289 5540

Email: [hta@health.gov.au](mailto:hta@health.gov.au)

Website: [www.msac.gov.au](http://www.msac.gov.au)

# PART 1 – APPLICANT DETAILS

## 1. Applicant details (primary and alternative contacts)

Corporation / partnership details (where relevant):

Corporation name: Pfizer Australia Pty Ltd

ABN: **REDACTED**

Business trading name: Pfizer Australia Pty Ltd

Primary contact name: **REDACTED**

Primary contact numbers

Business: **REDACTED**

Mobile: **REDACTED**

Email: **REDACTED**

Alternative contact name: **REDACTED**

Alternative contact numbers

Business: **REDACTED**

Mobile: **REDACTED**

Email: **REDACTED**

## 2. (a) Are you a lobbyist acting on behalf of an Applicant?

Yes

No

## (b) If yes, are you listed on the Register of Lobbyists?

Yes

No

# PART 2 – INFORMATION ABOUT THE PROPOSED MEDICAL SERVICE

## 3. Application title

Radionuclide imaging using 99mTc-PYP, 99mTc-HDP or 99mTc-DPD for the diagnosis of transthyretin amyloid cardiomyopathy.

## 4. Provide a succinct description of the medical condition relevant to the proposed service (no more than 150 words – further information will be requested at Part F of the Application Form)

Transthyretin amyloid cardiomyopathy (ATTR-CM) is a life-threatening disease characterised by accumulation of amyloid fibrils composed of misfolded transthyretin protein in the heart.<sup>1</sup> Misfolded monomers or oligomers of transthyretin are deposited in the myocardium, leading to cardiomyopathy and symptoms of heart failure.

ATTR-CM is a late-onset disease occurring predominately in male patients aged 60 years or older.<sup>2</sup> ATTR-CM can be inherited as an autosomal dominant trait caused by pathogenic mutations in the transthyretin gene *TTR* (ATTRm) or by deposition of wild-type transthyretin protein (ATTRwt), previously called senile systemic amyloidosis.<sup>3</sup>

## 5. Provide a succinct description of the proposed medical service (no more than 150 words – further information will be requested at Part 6 of the Application Form)

Radionuclide scintigraphy with 99mTc-labeled pyrophosphate (PYP), 99mTc-labeled oxidronate (HDP) or 99mTc-labeled 3,3-diphosphono-1,2-propanodicarboxylic acid (DPD) is sensitive and specific for imaging cardiac ATTR amyloid and enables a diagnosis of ATTR-CM.

A standard protocol includes whole-body scans after injection.<sup>4</sup> Heart and whole-body retention and heart to whole-body retention ratio can be semi-quantitatively analysed from early whole-body counts.<sup>5</sup> Visual scoring is performed with late images (0: no cardiac and normal bone uptake; 1: mild cardiac < bone uptake; 2: moderate cardiac and attenuated bone uptake; and; 3: strong cardiac and attenuated bone uptake).

## 6. (a) Is this a request for MBS funding?

- Yes  
 No

## If yes, is the medical service(s) proposed to be covered under an existing MBS item number(s) or is a new MBS item(s) being sought altogether?

- Amendment to existing MBS item(s)  
 New MBS item(s)

<sup>1</sup> Rapezzi C, Quarta CC, Riva L, et al. Transthyretin-related amyloidoses and the heart: a clinical overview. *Nat Rev Cardiol*, 2010; 7: 398-408.

<sup>2</sup> Ruberg FL, Berk JL. Transthyretin (TTR) cardiac amyloidosis. *Circulation*, 2012; 126: 1286-300.

<sup>3</sup> Maurer MS, Hanna M, Grogan M, et al. Genotype and phenotype of transthyretin cardiac amyloidosis: THAOS (Transthyretin Amyloid Outcome Survey). *J Am Coll Cardiol*, 2016; 68: 161-72.

<sup>4</sup> Lairez O, Pascal P, Victor G, Bastié D, Lavie-Badie Y, Pierre A, Cassol E and Berry I. Bone scintigraphy for cardiac amyloidosis imaging: Past, present and future. *Médecine Nucléaire*, 2017; 41:108–114.

<sup>5</sup> Rapezzi C, Quarta CC, Guidalotti PL, et al. Usefulness and limitations of 99mTc-3,3-diphosphono-1,2-propanodicarboxylic acid scintigraphy in the aetiological diagnosis of amyloidotic cardiomyopathy. *Eur J Nucl Med Mol Imaging*, 2011;38:470–8.

**(b) If an amendment to an existing item(s) is being sought, please list the relevant MBS item number(s) that are to be amended to include the proposed medical service:**

N/A

**(c) If an amendment to an existing item(s) is being sought, what is the nature of the amendment(s)?**

- i.  An amendment to the way the service is clinically delivered under the existing item(s)
- ii.  An amendment to the patient population under the existing item(s)
- iii.  An amendment to the schedule fee of the existing item(s)
- iv.  An amendment to the time and complexity of an existing item(s)
- v.  Access to an existing item(s) by a different health practitioner group
- vi.  Minor amendments to the item descriptor that does not affect how the service is delivered
- vii.  An amendment to an existing specific single consultation item
- viii.  An amendment to an existing global consultation item(s)
- ix.  Other (please describe below):

Insert description of 'other' amendment here

**(d) If a new item(s) is being requested, what is the nature of the change to the MBS being sought?**

- i.  A new item which also seeks to allow access to the MBS for a specific health practitioner group
- ii.  A new item that is proposing a way of clinically delivering a service that is new to the MBS (in terms of new technology and / or population)
- iii.  A new item for a specific single consultation item
- iv.  A new item for a global consultation item(s)

**(e) Is the proposed service seeking public funding other than the MBS?**

- Yes
- No

**(f) If yes, please advise:**

The scintigraphy may be performed in public hospitals and be funded by the hospital

**7. What is the type of service:**

- Therapeutic medical service
- Investigative medical service
- Single consultation medical service
- Global consultation medical service
- Allied health service
- Co-dependent technology
- Hybrid health technology

Please note that the Sponsor seeks advice from MSAC on whether a co-dependent technology submission is required. Patients need to be diagnosed as having ATTR-CM prior to initiation of treatment with tafamidis (**REDACTED**).

**8. For investigative services, advise the specific purpose of performing the service (which could be one or more of the following):**

- i.  To be used as a screening tool in asymptomatic populations
- ii.  Assists in establishing a diagnosis in symptomatic patients
- iii.  Provides information about prognosis
- iv.  Identifies a patient as suitable for therapy by predicting a variation in the effect of the therapy
- v.  Monitors a patient over time to assess treatment response and guide subsequent treatment decisions

**9. Does your service rely on another medical product to achieve or to enhance its intended effect?**

- Pharmaceutical / Biological
- Prosthesis or device
- No

**10. (a) If the proposed service has a pharmaceutical component to it, is it already covered under an existing Pharmaceutical Benefits Scheme (PBS) listing?**

Yes

No

**(b) If yes, please list the relevant PBS item code(s):**

Insert PBS item code(s) here

**(c) If no, is an application (submission) in the process of being considered by the Pharmaceutical Benefits Advisory Committee (PBAC)?**

Yes (please provide PBAC submission item number below)

No

**REDACTED**

**(d) If you are seeking both MBS and PBS listing, what is the trade name and generic name of the pharmaceutical?**

Trade name: **REDACTED**

Generic name: tafamidis

**11. (a) If the proposed service is dependent on the use of a prosthesis, is it already included on the Prostheses List?**

Yes

No

**(b) If yes, please provide the following information (where relevant):**

Billing code(s): Insert billing code(s) here

Trade name of prostheses: Insert trade name here

Clinical name of prostheses: Insert clinical name here

Other device components delivered as part of the service: Insert description of device components here

**(c) If no, is an application in the process of being considered by a Clinical Advisory Group or the Prostheses List Advisory Committee (PLAC)?**

Yes

No

**(d) Are there any other sponsor(s) and / or manufacturer(s) that have a similar prosthesis or device component in the Australian market place which this application is relevant to?**

Yes

No

**(e) If yes, please provide the name(s) of the sponsor(s) and / or manufacturer(s):**

Insert sponsor and/or manufacturer name(s) here

**12. Please identify any single and / or multi-use consumables delivered as part of the service?**

Single use consumables: Insert description of single use consumables here

Multi-use consumables: Insert description of multi use consumables here

## PART 3 – INFORMATION ABOUT REGULATORY REQUIREMENTS

13. (a) If the proposed medical service involves the use of a medical device, in-vitro diagnostic test, pharmaceutical product, radioactive tracer or any other type of therapeutic good, please provide the following details:

Type of therapeutic good	Product details	AUSTR No.	Sponsor's name
Radioactive tracer	RADPHARM PYP kit for the production of Technetium (99mTc) tin pyrophosphate powder for injection multidose vial	14328	Global Medical Solutions Australia Pty Limited T/A Radpharm Scientific
Radioactive tracer	AUSTIN HEALTH STANNOUS PYROPHOSPHATE Kit for preparation of Technetium (99mTc) stannous pyrophosphate powder for injection multidose vial	54211	Austin Health
Radioactive tracer	TECHNESCAN PYP Kit for preparation of Technetium (99mTc) pyrophosphate powder for injection multidose vial	20025	Landauer Radiopharmaceuticals Pty Ltd
Radioactive tracer	RADPHARM HDP sodium oxidronate 3.15 mg kit for the preparation of technetium (99m Tc) oxidronate for injection	160732	Global Medical Solutions Australia Pty Limited T/A Radpharm Scientific
Radioactive tracer	TECHNESCAN HDP Kit for preparation of Technetium (99 mTc) oxidronate powder for injection multidose vial	12742	Guerbet Australia Pty Ltd
Radioactive tracer	TECHNESCAN HDP kit for preparation of Technetium [99mTc] oxidronate powder for injection vial	75500	Landauer Radiopharmaceuticals Pty Ltd
Radioactive tracer	Kit for the preparation of Technetium [99mTc] 3,3-diphosphono-1,2-propanedicarboxylic acid (DPD) injection	Not registered	Cis Bio International

(b) Is the medical device classified by the TGA as either a Class III or Active Implantable Medical Device (AIMD) against the TGA regulatory scheme for devices?

- Class III  
 AIMD  
 N/A

14. (a) Is the therapeutic good to be used in the service exempt from the regulatory requirements of the *Therapeutic Goods Act 1989*?

- Yes (If yes, please provide supporting documentation as an attachment to this application form)  
 No

(b) If no, has it been listed or registered or included in the Australian Register of Therapeutic Goods (ARTG) by the Therapeutic Goods Administration (TGA)?

- Yes (if yes, please provide details below)  
 No

**ARTG listing, registration or inclusion number: 14328, 54211, 20025**

TGA approved indication(s), if applicable: Technetium [<sup>99m</sup>Tc] labelled erythrocytes are used in the non-invasive evaluation of cardiac ventricular function and heart wall motion.

**ARTG listing, registration or inclusion number: 160732, 12742, 75500**

TGA approved indication(s), if applicable: Technetium [<sup>99m</sup>Tc] sodium oxidronate may be used as a skeletal imaging agent to delineate areas of altered osteogenesis in adult patients.

TGA approved purpose(s), if applicable: As per indications

**15. If the therapeutic good has not been listed, registered or included in the ARTG, is the therapeutic good in the process of being considered for inclusion by the TGA?**

Yes (please provide details below)

No

Note <sup>99m</sup>Tc-labeled 3,3-diphosphono-1,2-propanodicarboxylic acid (DPD) is imported under the TGA's Category B Special Access Scheme by two of the amyloid clinics. The amyloid specialists consulted indicated that the company (CIS bio international, B.P. 32 - 91192 GIF-SUR-YVETTE CEDEX, FRANCE) has not attempted to, or been asked to, submit an application to the TGA. They requested that the fact that DPD is used by the Westmead and Brisbane clinics as well as the pivotal role in validation of non-biopsy diagnosis of cardiac ATTR could be mentioned in the application and that whether the manufacturer seeks TGA register will ultimately be up to the manufacturer in question.

**16. If the therapeutic good is not in the process of being considered for listing, registration or inclusion by the TGA, is an application to the TGA being prepared?**

Yes (please provide details below)

No

Please see 14. above

## PART 4 – SUMMARY OF EVIDENCE

17. Provide an overview of all key journal articles or research published in the public domain related to the proposed service that is for your application (limiting these to the English language only). *Please do not attach full text articles, this is just intended to be a summary.*

-	Type of study design*	Title of journal article or research project (including any trial identifier or study lead if relevant)	Short description of research (max 50 words)**	Website link to journal article or research (if available)	Date of publication ***
1.	Observational	<sup>99m</sup> Tc-DPD scintigraphy in transthyretin-related familial amyloidotic polyneuropathy	Eight patients (four males, four females; mean age 54.4±8.3 years) with ATTR-FAP proven by immunohistochemistry and molecular analysis and control group (ten oncological out-patients [five males, five females; age 53.4±8.5 years]) without bony metastases were had DPD scintigraphy. Three FAP patients with highest cardiac tracer uptake had cardiomyopathy or arrhythmia.	<a href="https://rd.springer.com/article/10.1007/s00259-001-0730-0">https://rd.springer.com/article/10.1007/s00259-001-0730-0</a>	2002
2.	Observational	Noninvasive aetiologic diagnosis of cardiac amyloidosis using <sup>99m</sup> Tc-3,3-diphosphono-1,2-propanodicarboxylic acid scintigraphy	Patients with amyloidosis and echocardiographic evidence had DPD scintigraphy. ATTR-related (group A; n = 15) and AL (group B; n = 10) patients comparable for LV mass and renal function. Sensitivity and specificity of scintigraphy were both 100% for group A patients; in group B, sensitivity was 0% and specificity was 100%.	<a href="https://www.sciencedirect.com/science/article/pii/S0735109705014075">https://www.sciencedirect.com/science/article/pii/S0735109705014075</a>	2005
3.	Observational	Role of <sup>99m</sup> Tc-DPD scintigraphy in diagnosis and prognosis of hereditary transthyretin-related cardiac amyloidosis	63 patients with ATTR were evaluated: 40 with and 23 without echocardiographically diagnosed AC. Myocardial uptake of DPD was semi-quantitatively and visually assessed at 5 minutes and 3 hours.	<a href="https://www.sciencedirect.com/science/article/pii/S1936878X11002701">https://www.sciencedirect.com/science/article/pii/S1936878X11002701</a>	2011
4.	Observational	Usefulness and limitations of <sup>99m</sup> Tc-3,3-diphosphono-1, 2-propanodicarboxylic acid scintigraphy in the aetiological	Included 45 patients with TTR-AC (28 mutant and 17 wild-type), 34 patients with AL AC and 15 non-affected controls.	<a href="https://rd.springer.com/article/10.1007/s00259-010-1642-7">https://rd.springer.com/article/10.1007/s00259-010-1642-7</a>	2011



-	Type of study design*	Title of journal article or research project (including any trial identifier or study lead if relevant)	Short description of research (max 50 words)**	Website link to journal article or research (if available)	Date of publication***
		diagnosis of amyloidotic cardiomyopathy	Positive and negative predictive accuracy of visual scoring were: 80 and 100% (visual score $\geq 1$ ); 88 and 100% (visual score $\geq 2$ ); and 100 and 68% (visual score = 3).		
5.	Observational	Technetium pyrophosphate SPECT imaging for non-invasive identification of transthyretin cardiac amyloidosis	PYP SPECT imaging was performed in 12 subjects (biopsy proven AL cardiac amyloidosis, 5; ATTR amyloid from V122I, 3 and ATTR amyloid wild type disease, 3; and healthy controls, 2). ATTR amyloid patients demonstrated marked uptake. Controls had no uptake and AL patients had uptake in 20% of cases.	Link not available. Publication can be found at: Journal of Cardiac Failure, 2011; 17 (8) p.S101-S102	2011
6.	Observational	Defining the diagnosis in echocardiographically suspected senile systemic amyloidosis	Patients (N=67) underwent DPD scintigraphy from 2004 to 2011 for suspected SSA. Visual DPD myocardial uptake was present in 51 patients and absent in 16. EMB revealed TTR-mutations in some patients but not in patients with SSA. No TTR mutations were found in patients with negative scintigraphy.	<a href="https://rd.springer.com/article/10.1007/s12350-016-0610-4">https://rd.springer.com/article/10.1007/s12350-016-0610-4</a>	2012
7.	Observational	Role of cardiac scintigraphy with $^{99m}\text{Tc}$ -DPD in the differentiation of cardiac amyloidosis subtype	Diagnostic accuracy of DPD scintigraphy in differentiating between monoclonal immunoglobulin light chain and TTR-CM was investigated. Nineteen patients with cardiac amyloidosis were included: 8 with TTR-CM (group A) and 11 with light chain amyloidosis (group B).	<a href="https://www.sciencedirect.com/science/article/pii/S1885585712000564?via%3Dihub">https://www.sciencedirect.com/science/article/pii/S1885585712000564?via%3Dihub</a>	2012
8.	Observational	Accuracy of $^{99m}\text{Tc}$ -HMPD myocardial scintigraphy for the diagnosis of cardiac involvement in patients with familial amyloid polyneuropathy	Twenty four consecutive patients with familial TTR related FAP (13 females, aged $42 \pm 12$ years) were included and cardiac involvement evaluated. Nine patients presented cardiac HMPD uptake (8 intense, 1 moderate), all with severe cardiac involvement,	Link not available. Publication can be found at: Eur J Nucl Med Mol Imaging (2012) 39 (Suppl 2):S155–S303	2012

-	<b>Type of study design*</b>	<b>Title of journal article or research project (including any trial identifier or study lead if relevant)</b>	<b>Short description of research (max 50 words)**</b>	<b>Website link to journal article or research (if available)</b>	<b>Date of publication***</b>
			corresponding to 43% of patients diagnosed with cardiac amyloidosis.		
9.	Observational	<sup>99m</sup> Tc-pyrophosphate scintigraphy for differentiating light-chain cardiac amyloidosis from the transthyretin-related familial and senile cardiac amyloidoses	Forty-five subjects (12 AL, 16 ATTR wild type, and 17 ATTR mutants) underwent PYP scintigraphy and single-photon positive emission computed tomography cardiac. Myocardial tracer retention showed 97% sensitivity and 100% specificity for identifying ATTR cardiac amyloidosis.	<a href="https://www.ahajournals.org/doi/10.1161/CIRCIMAGING.112.000132">https://www.ahajournals.org/doi/10.1161/CIRCIMAGING.112.000132</a>	2013
10.	Observational	Skeletal scintigraphy indicates disease severity of cardiac involvement in patients with senile systemic amyloidosis	36 SSA patients (71.6 [64.7–82.7] years) were evaluated by electrocardiography, echocardiography, laboratory tests, and DPD scintigraphy (n=20). DPD heart retention was 7.8 [2.4–11.0]%. DPD heart retention was 7.8 [2.4–11.0]%	<a href="https://www.sciencedirect.com/science/article/pii/S0167527311006802">https://www.sciencedirect.com/science/article/pii/S0167527311006802</a>	2013
11.	Observational	<sup>99m</sup> Tc-HDP scintigraphy in the diagnostic workup of cardiac amyloidosis: preliminary results.	Included a group of 12 patients (7 males and 5 females; mean age 80 years) who had been admitted to hospital with hypertrophic cardiomyopathy and suspected cardiac amyloidosis. Workup included HDP scintigraphy.	Link not available. Publication can be found at: Eur J Nucl Med Mol Imaging S248 (2013) 40 (Suppl 2):S1–S477	2013
12.	Retrospective cohort study	Preclinical identification of TTR-related amyloidosis (hereditary and wild type) with <sup>99m</sup> Tc-DPD scintigraphy: a cohort study of 12,400 subjects	DPD scintigraphies, clinical, instrumental and incidental myocardial tracer uptake were reviewed. Myocardial uptake was detected in 45 subjects (0.36%): 28 males (62%), median age 81. Prevalence was higher among men and increased progressively with age.	<a href="https://academic.oup.com/eurheartj/article/35/suppl_1/1/541954">https://academic.oup.com/eurheartj/article/35/suppl_1/1/541954</a>	2014
13.	Observational	Noninvasive risk stratification of patients with transthyretin amyloidosis	Noninvasive parameters were evaluated for prediction of all-cause mortality in 70 patients with ATTR. Echocardiography and plasma levels of biomarkers were correlated with scintigraphy.	<a href="https://www.sciencedirect.com/science/article/pii/S1936878X14002010?via%3Dihub">https://www.sciencedirect.com/science/article/pii/S1936878X14002010?via%3Dihub</a>	2014
14.	Observational	Bone scintigraphy with <sup>99m</sup> technetium-hydroxymethylene	Forty-one patients underwent clinical examinations, echocardiography, ECG, measurement of cardiac biomarkers and bone scintigraphy (planar imaging and SPECT-CT) and	<a href="https://www.tandfonline.com/doi/full/10.3109/13506129.2013.871250">https://www.tandfonline.com/doi/full/10.3109/13506129.2013.871250</a>	2014

-	Type of study design*	Title of journal article or research project (including any trial identifier or study lead if relevant)	Short description of research (max 50 words)**	Website link to journal article or research (if available)	Date of publication***
		diphosphonate allows early diagnosis of cardiac involvement in patients with transthyretin-derived systemic amyloidosis	were diagnosed as: (1) carriers of amyloidogenic TTR mutation [11], (2) ATTR amyloidosis without echocardiographically-defined cardiac amyloidosis (AC) [19], and (3) ATTR amyloidosis with echocardiographically-defined cardiac amyloidosis [11].		
15.	Observational	Utility and limitations of 3,3-diphosphono-1, 2-propanodicarboxylic acid scintigraphy in systemic amyloidosis	Reports on 321 patients with suspected cardiac amyloidosis who underwent scintigraphy. Included ATTRwt in 94 (29%), ATTR-Val122Ile in 38 (12%), ATTRmt in 46 (14%), AL in 44 (14%), secondary (AA) amyloidosis in three (1%), other hereditary amyloidosis types in nine (3%), undetermined types in two (0.5%), and 85 (26.5%) patients without systemic amyloidosis.	<a href="https://academic.oup.com/ehjcmagimg/article/15/11/1289/2399634">https://academic.oup.com/ehjcmagimg/article/15/11/1289/2399634</a>	2014
16.	Observational	Usefulness of <sup>99m</sup> Tc-DPD scintigraphy in preclinical identification of TTR-related amyloidosis (hereditary and wild type): a cohort study of 12400 subjects	DPD scintigraphies performed between 2008 and May 2013 in outpatients referred to Nuclear Medicine Unit for oncologic or rheumatologic reasons were reviewed and clinical and instrumental details of patients with incidental myocardial tracer uptake assessed. Incidental myocardial uptake was detected in 45 subjects (0.36%): 28 males (62%), median age 81 [77-84].	Link not available. Publication can be found at: Giornale Italiano di Cardiologia, 2014; 4 (suppl 2):e144	2014
17.	Observational	Usefulness of <sup>99m</sup> Tc-HMDP scintigraphy for the etiologic diagnosis and prognosis of cardiac amyloidosis	121 patients underwent HMDP scintigraphy. CA was diagnosed in AL (n=14) and wt-TTR (n=21). Among m-TTR (n=34), 26 had CA, 4 neuropathy without CA and 4 were asymptomatic carriers. HMDP cardiac uptake occurred in all wt-TTR, in m-TTR with CA except two and in one AL. Visual score $\geq 2$ was 100% specific for diagnosing TTR-CA.	<a href="https://doi.org/10.3109/13506129.2015.1072089">https://doi.org/10.3109/13506129.2015.1072089</a>	2015
18.	Observational	The index of the maximum accumulation <sup>99m</sup> Tc-DPD in the myocardium of patients with transthyretin (TTR) cardiac	Evaluation and comparison of Mc of DPD in the myocardium in patients with TTR cardiac amyloidosis (1 woman and 4 men) and control group (41 women and 36 men) of persons $\geq 70$ years without known heart disease.	Link not available. Publication can be found at: Eur J Nucl Med Mol Imaging (2015) 42 (Suppl 1):S1–S924	2015

-	Type of study design*	Title of journal article or research project (including any trial identifier or study lead if relevant)	Short description of research (max 50 words)**	Website link to journal article or research (if available)	Date of publication ***
		amyloidosis and of older people without known heart disease			
19.	Observational	Technetium pyrophosphate uptake in transthyretin cardiac amyloidosis: associations with echocardiographic disease severity and outcomes	A retrospective analysis was performed of 75 patients who underwent PYP scintigraphy and 48 patients were diagnosed with ATTR.	<a href="https://link.springer.com/article/10.1007%2Fs12350-016-0768-9">https://link.springer.com/article/10.1007%2Fs12350-016-0768-9</a>	2016
20.	Observational	Nonbiopsy diagnosis of cardiac transthyretin amyloidosis	Results of bone scintigraphy and biochemical investigations were analysed from 1,217 patients with suspected TTR-CM. The combined findings of grade 2 or 3 myocardial radiotracer uptake and the absence of a monoclonal protein in serum or urine had a specificity and positive predictive value for cardiac ATTR amyloidosis of 100%.	<a href="https://www.ahajournals.org/doi/10.1161/CIRCULATIONAHA.116.021612">https://www.ahajournals.org/doi/10.1161/CIRCULATIONAHA.116.021612</a>	2016
21.	Case-control	Quantitative comparison between amyloid deposition detected by <sup>99m</sup> Tc-diphosphonate imaging and myocardial deformation evaluated by strain echocardiography in transthyretin-related cardiac amyloidosis	Twenty-eight patients with transthyretin mutation and 14 controls had echocardiography. DPD scintigraphy was used to quantify CA and revealed accumulation in 14/28 patients (CA group) and no accumulation (no-CA group) in 14. A correlation was found between the scintigraphic HRI and LV septal thickness ( $\rho=0.72$ ), E/E' ( $\rho=0.46$ ) and GLS ( $\rho=-0.40$ ).	Link not available. Publication can be found at: Circ J, 2016; 80: 1998 – 2003	2016
22.	Observational	<sup>99m</sup> Tc-hydroxy-diphosphate tracer ( <sup>99m</sup> Tc HDP) bone scintigraphy: an easily accessible, rapid, non-invasive diagnostic tool for cardiac amyloidosis	25 patients with amyloidosis diagnosed by cardiac MRI and/or biopsy had HDP bone scintigraphy. 18 were confirmed with ATTR and 7 with AL. Two ATTR patients had hereditary disease, the remainder were wild-type. 17 (94%) patients with ATTR and 2 (29%) AL had positive scans.	<a href="http://www.bloodjournal.org/content/128/22/3557?sso-checked=true">http://www.bloodjournal.org/content/128/22/3557?sso-checked=true</a>	2016

-	Type of study design*	Title of journal article or research project (including any trial identifier or study lead if relevant)	Short description of research (max 50 words)**	Website link to journal article or research (if available)	Date of publication ***
23.	Observational	Utility and limitations of 3,3-diphosphono-1, 2-propanodicarboxylic acid scintigraphy in systemic amyloidosis	All 158 patients with ATTR amyloidosis and cardiac involvement had cardiac DPD uptake, with median Grade 2 intensity. Thirteen ATTR amyloidosis patients without clinical evidence of cardiac involvement also demonstrated DPD cardiac uptake. Eighteen of 35 (51%) AL patients with cardiac involvement had DPD cardiac uptake (median Grade 1 intensity).	<a href="https://www.jstage.jst.go.jp/article/circj/80/9/80_CJ-16-0209/_article/-char/en">https://www.jstage.jst.go.jp/article/circj/80/9/80_CJ-16-0209/_article/-char/en</a>	2016
24.	Observational	Standardization of <sup>99m</sup> Techetium pyrophosphate imaging methodology to diagnose TTR cardiac amyloidosis	104 scans from 45 subjects with biopsy-proven ATTR-CA or AL amyloidosis were assessed. The correlation between H/CL ratios and reproducibility of semiquantitative visual scores were evaluated. Correlation of H/CL ratios was strong ( $r \geq 0.92$ ) and reproducibility of semiquantitative visual scores was high (Kappa = 95%).	<a href="https://rd.springer.com/article/10.1007/s12350-016-0610-4">https://rd.springer.com/article/10.1007/s12350-016-0610-4</a>	2016
25.	Observational	Serial scanning with technetium pyrophosphate ( <sup>99m</sup> Tc-PYP) in advanced ATTR cardiac amyloidosis	Twenty subjects with ATTR-CA (10 wild type, 10 mutant) underwent serial PYP planar cardiac imaging. Serial PYP scanning did not show significant changes over an average 1.5 years of follow-up despite obvious clinical progression.	<a href="https://rd.springer.com/article/10.1007/s12350-015-0261-x">https://rd.springer.com/article/10.1007/s12350-015-0261-x</a>	2016
26.	Observational	Single photon emission computerized tomography imaging can quantify regional distribution of <sup>99m</sup> Techetium pyrophosphate uptake in patients with transthyretin cardiac amyloidosis	SPECT scans of 45 patients (36 male, 73.5 ± 8.0 years) with biopsy proven TTR were analysed. The distal septum had significantly higher counts compared to other 8 segments ( $p < .0001$ ). Intraobserver agreement was ≥ 90%. Inter-observer agreement was 90% for all segments except for lateral distal segment which was 80%.	<a href="https://www.sciencedirect.com/science/article/pii/S0735109716318216">https://www.sciencedirect.com/science/article/pii/S0735109716318216</a>	2016
27.	Observational	The utility of <sup>99m</sup> Tc-DPD scintigraphy in the diagnosis of cardiac amyloidosis: an Australian experience	Patients with AL and ATTR (wild-type and inherited) cardiac amyloidosis underwent DPD scintigraphy. DPD scintigraphy was positive in 2 (25%) AL, and 13 (100%) ATTR patients. A grade of 2 or greater was 100% sensitive	<a href="https://www.sciencedirect.com/science/article/pii/S1443950617300616?via%3Dihub">https://www.sciencedirect.com/science/article/pii/S1443950617300616?via%3Dihub</a>	2017

-	Type of study design*	Title of journal article or research project (including any trial identifier or study lead if relevant)	Short description of research (max 50 words)**	Website link to journal article or research (if available)	Date of publication ***
			and 88% specific for the diagnosis of ATTR cardiac amyloidosis.		
28.	Observational	Early phase <sup>99</sup> Tc-HMDP scintigraphy for the diagnosis and typing of cardiac amyloidosis	Of 135 subjects who underwent HMDP-scintigraphy, 93 were diagnosed with amyloidosis or genetic TTR mutation. Nineteen had AL, 41 had m-TTR, and 33 had wt-TTR. Cardiac involvement was found in patients with AL or wt-TTR amyloidosis and 33 patients with m-TTR.	<a href="https://www.sciencedirect.com/science/article/pii/S1936878X16303527?via%3Dihub">https://www.sciencedirect.com/science/article/pii/S1936878X16303527?via%3Dihub</a>	2017
29.	Observational	Apical sparing pattern of left ventricular myocardial <sup>99m</sup> Tc-HMDP uptake in patients with transthyretin cardiac amyloidosis	Sixty-one TTR-CA patients underwent HMDP scintigraphy: 29 had wt-TTR-CA and 32 had m-TTR-CA. Early myocardial HMDP uptake occurred in all TTR-CA patients.	<a href="https://link.springer.com/article/10.1007%2Fs12350-017-0894-z">https://link.springer.com/article/10.1007%2Fs12350-017-0894-z</a>	2017
30.	Observational	Accuracy of <sup>99m</sup> Tc-hydroxymethylene diphosphonate scintigraphy for diagnosis of transthyretin cardiac amyloidosis	Patients who had HMDP scintigraphy were retrospectively evaluated. Sixty-five patients were diagnosed with CA, while it was excluded in 20 subjects with LVH of various aetiologies. HMDP scintigraphy showed 100% sensitivity and 96% specificity for TTR-CA identification.	<a href="https://link.springer.com/article/10.1007%2Fs12350-017-0922-z">https://link.springer.com/article/10.1007%2Fs12350-017-0922-z</a>	2017
31.	Observational	First Australian registry of patients with wild type cardiac amyloidosis (ATTRwt): Queensland experience	Included 35 patients with ATTRwt (mean age 77 years, all male). DPD scintigraphy was positive in 100% of patients with cardiac ATTRwt.	<a href="https://academic.oup.com/eurheartj/article/38/suppl_1/ehx502.1955/4088288">https://academic.oup.com/eurheartj/article/38/suppl_1/ehx502.1955/4088288</a>	2017
32.	Observational	Bone scintigraphy in left ventricular hypertrophy. Preliminary results of a new service in a tertiary hospital	56 patients with LVH were scanned. 17 patients (30%) had positive DPD scans (2 grade 1, 14 grade 2 and 1 grade 3). Patients with positive DPD scans were older (81±8 vs 68±13, p<0.001) with more LVH (septum 17±2mm vs 14±4mm, p=0.016; posterior wall 16±4mm vs 12±4mm, p=0.003).	<a href="https://academic.oup.com/ehjcmaging/article/18/suppl_1/i20/3806224">https://academic.oup.com/ehjcmaging/article/18/suppl_1/i20/3806224</a>	2017
33.	Observational	Tc99m-pyrophosphate scintigraphy using solid-state	Tc99m-PYP scintigraphy was performed on 23 patients with known or suspected cardiac amyloidosis using traditional	<a href="https://academic.oup.com/ehjcmaging/article/18/suppl_1/i58/3806229">https://academic.oup.com/ehjcmaging/article/18/suppl_1/i58/3806229</a>	2017

-	Type of study design*	Title of journal article or research project (including any trial identifier or study lead if relevant)	Short description of research (max 50 words)**	Website link to journal article or research (if available)	Date of publication ***
		detector alcyone SPECT: comparison to planar imaging for the diagnosis of transthyretin cardiac amyloidosis	dual-head, wide-field of view Anger and GE Alcyone solid-state detector cameras following the same injection of Tc99m-PYP.		
34.	Observational	Diagnostic score for the detection of cardiac amyloidosis in patients with left ventricular hypertrophy and impact on prognosis	One hundred and fourteen patients with LVH underwent a CMR and HMDP allowing discrimination of three groups of diagnoses: CA (n=50 including 31, 18 and 1 ATTR, AL and AA amyloidosis), hypertrophic cardiomyopathy (n=19) and unspecific cardiomyopathy (n=45).	<a href="https://www.tandfonline.com/doi/full/10.1080/13506129.2017.1333956">https://www.tandfonline.com/doi/full/10.1080/13506129.2017.1333956</a>	2017
35.	Observational	Prognostic utility of the Perugini grading of <sup>99m</sup> Tc-DPD scintigraphy in transthyretin (ATTR) amyloidosis and its relationship with skeletal muscle and soft tissue amyloid	Patient survival from time of DPD scintigraphy was determined in 602 patients with ATTR amyloidosis, including 377 with wild-type ATTR (ATTRwt) and 225 with mutant ATTR (ATTRm) amyloidosis.  DPD scintigraphy is sensitive for identification of cardiac ATTR amyloid, but stratification by Perugini grade of positivity at diagnosis has no prognostic significance.	<a href="https://academic.oup.com/ehjcimagining/article/18/12/1344/2968367">https://academic.oup.com/ehjcimagining/article/18/12/1344/2968367</a>	2017
36.	Observational	Diagnostics of wild-type transthyretin cardiomyopathy and its clinical presentation in Czech patients - a single centre experience.	The study group included 16 patients (14 males, 2 females; mean age 80±6 years) diagnosed with wild-type TTR-CM from 2010-2016. The diagnosis of TTR-CM was based on index of maximal myocardial accumulation at DPD SPECT-CT.	<a href="https://onlinelibrary.wiley.com/doi/epdf/10.1002/ejhf.833">https://onlinelibrary.wiley.com/doi/epdf/10.1002/ejhf.833</a>	2017
37.	Observational	Myocardial technetium-99m methylene diphosphonate uptake and left ventricular motion in transthyretin related cardiac amyloidosis	Ten patients with TTR-related cardiac amyloidosis had whole body scans 180 minutes after MDP injection. After planar imaging a gated SPECT acquisition was performed.  MTU was expressed as % of whole body counts subtracted by the bladder radioactivity content.	Link not available. Publication can be found at: Eur J Nucl Med Mol Imaging (2017) 44 (Suppl 2):S119–S956	2017

-	Type of study design*	Title of journal article or research project (including any trial identifier or study lead if relevant)	Short description of research (max 50 words)**	Website link to journal article or research (if available)	Date of publication***
38.	Observational	Role of bone scintigraphy with technetium ( <sup>99m</sup> Tc) 3,3-diphosphono-1,2-propanedicarboxylic acid (DPD) in the identification of patients with cardiac amyloidosis (CA); our experience	In the period between July 2015 and August 2016, 20 patients with suspected cardiac amyloidosis were enrolled (12 males and 8 females; mean age 77 years. Patients were scanned after DPD injection. In positive patients SPECT of thoracic region was performed.	Link not available. Publication can be found at: Clin Transl Imaging (2017) 5 (Suppl 1):S1–S153	2017
39.	Observational	Quantitation of <sup>99m</sup> Tc-DPD uptake in patients with transthyretin-related cardiac amyloidosis	Three methods of quantitation were developed and tested on 74 patients with proven cardiac ATTR amyloidosis who had recently undergone DPD planar whole-body imaging and SPECT-CT.	<a href="https://www.tandfonline.com/doi/full/10.1080/13506129.2018.1520087">https://www.tandfonline.com/doi/full/10.1080/13506129.2018.1520087</a>	2018
40.	Observational	Early-phase myocardial uptake intensity of <sup>99m</sup> Tc-HMDP vs <sup>99m</sup> Tc-DPD in patients with hereditary transthyretin-related cardiac amyloidosis	Six patients with biopsy-proven diagnosis of TTR-CM and characteristic amyloid fibril composition underwent early-phase HMDP myocardial scintigraphy and were later assessed by DPD scintigraphy. Regional distribution of the two radiotracers was well correlated on bull's eyes analysis.	<a href="https://link.springer.com/article/10.1007%2Fs12350-016-0707-9">https://link.springer.com/article/10.1007%2Fs12350-016-0707-9</a>	2018
41.	Observational	Regional variation in technetium pyrophosphate uptake in transthyretin cardiac amyloidosis and impact on mortality	Patients with ATTR who underwent PYP scintigraphy were included. Overall, 54 patients with ATTR (mean age 78 ± 9 years, 76% male, 31% hereditary ATTR) were analysed. There was increased PYP uptake in basal and mid relative to apical LV segments, and apical-sparing LS pattern.	<a href="https://www.sciencedirect.com/science/article/pii/S1936878X17307660">https://www.sciencedirect.com/science/article/pii/S1936878X17307660</a>	2018
42.	Observational	Non-cardiac uptake of technetium-99m pyrophosphate in transthyretin cardiac amyloidosis	This was a retrospective analysis of 57 patients with ATTR who underwent PYP scintigraphy. Total and blood pool-corrected uptake in muscle groups were significantly less than myocardium and bone (P < 0.001).	<a href="https://link.springer.com/article/10.1007%2Fs12350-017-1166-7">https://link.springer.com/article/10.1007%2Fs12350-017-1166-7</a>	2018



-	Type of study design*	Title of journal article or research project (including any trial identifier or study lead if relevant)	Short description of research (max 50 words)**	Website link to journal article or research (if available)	Date of publication***
43.	Observational	Cardiac amyloidosis. Utility of bone seeking tracers scintigraphy in differentiation the subtype of amyloid	Seven patients with heart failure, concentric LVH, diastolic dysfunction and normal systolic function underwent PYP scintigraphy. Scintigraphic findings revealed a very intensive tracer uptake in the heart region compared to bone tissue (score 3) in all patients.	Website link not available. Can be found at: Eur J Nucl Med Mol Imaging (2018) 45 (Suppl 1): S1–S844	2018
44.	Observational	Apical sparing pattern of left ventricular myocardial <sup>99m</sup> Tc-HMDP uptake in patients with transthyretin-related cardiac amyloidosis	Aim of study was to investigate LV regional distribution of early-phase HMDP uptake in patients with TTR-CA. Early myocardial HMDP uptake occurred in all TTR-CA patients.	<a href="https://www.sciencedirect.com/science/article/pii/S1878648017306225?via%3Dihub">https://www.sciencedirect.com/science/article/pii/S1878648017306225?via%3Dihub</a>	2018
45.	Observational	Cardiac transthyretin amyloidosis: are we under-diagnosing and under-treating?	Fifty-two patients (51 male, one female) were diagnosed with TTR-wt from September 2014 to January 2018. Forty-eight patients underwent bone scintigraphy, all demonstrating cardiac uptake (Perugini score 3, 2, and 1 seen in 22, 24, and 2, respectively).	<a href="https://www.heartlungcirc.org/article/S1443-9506(18)30819-9/pdf">https://www.heartlungcirc.org/article/S1443-9506(18)30819-9/pdf</a>	2018
46.	Observational	Pattern of myocardial <sup>99m</sup> Tc-HMDP uptake and impact on myocardial function in patients with transthyretin cardiac amyloidosis	Fifty patients with TTR-CA underwent HMDP scintigraphy and echocardiography. Mean population age was 79 ± 10 years. Mean H/WB ratio was 12 ± 7. Myocardial HMDP uptake was correlated with H/WB ratio. Mean LVEF and global LS were 51 ± 10% and 2 10 ± 3%, respectively.	<a href="https://rd.springer.com/article/10.1007/s12350-018-1316-6">https://rd.springer.com/article/10.1007/s12350-018-1316-6</a>	2018
47.	Observational	Diagnostic accuracy of 99m-DPD SPECT scintigraphy in TTR-amyloidosis	SPECT scintigraphy with DPD was performed in 17 patients (m = 14 [82.4 %], f = 3 [17.6 %]). All patients underwent EMB biopsy for histologic and immunohistochemical evaluation. Three groups were generated according to the final diagnosis: ATTR (n = 7), AL (n = 5), no CA (n = 5).	Link not available. Article can be found at: European Journal of Heart Failure 2018 European Society of Cardiology, 20 (Suppl. S1), P569	2018

-	Type of study design*	Title of journal article or research project (including any trial identifier or study lead if relevant)	Short description of research (max 50 words)**	Website link to journal article or research (if available)	Date of publication ***
48.	Observational	The diagnostic role of <sup>99m</sup> Tc-PYP scintigraphy in the differential diagnoses of cardiac amyloidosis: preliminary results	14 patients received PYP scintigraphy which was positive for 5 patients (ATTR grade=3). One patient had grade=2 and had cardiac AL in myeloma. Of remaining 7 patients negative for ATTR (grade≤1), 3 had AL amyloidosis in MGUS, in 3 AL was excluded, while 1 had false positive for AL.	Link not available. Can be found at: Eur J Nucl Med Mol Imaging (2018) 45 (Suppl 1): S1–S844	2018
49.	Observational	A multi-centre study of cardiac amyloidosis in TAVI patients	Participants underwent DPD scintigraphy, which was graded using Perugini scoring system, prior to TAVI.  DPD scintigraphy was positive in 16 patients (13%, 95% CI: 8% to 20%). Perugini grade was 1 (n=5) and 2 (n=11). In DPD-positive cohort 44% were male (mean age 88±5 years) and those genotyped were all wild-type (n=7).	Link not available. Publication can be found at: Heart 2018;104(Suppl 5): A1–A16	2018
50.	Observational	Technetium pyrophosphate uptake in transthyretin cardiac amyloidosis: Associations with echocardiographic disease severity and outcomes	A retrospective analysis was performed of 75 patients who underwent PYP scintigraphy.  There were 48 patients diagnosed with ATTR.  Both semi-quantitative uptake grade and H/CL ratio were associated with all-cause mortality (P = 0.009 and 0.007, respectively) and all-cause mortality or heart failure hospitalisation (P = 0.001 and 0.020, respectively).	<a href="https://link.springer.com/article/10.1007%2Fs12350-016-0768-9">https://link.springer.com/article/10.1007%2Fs12350-016-0768-9</a>	2018
51.	Meta-analysis	Diagnostic accuracy of bone scintigraphy in the assessment of cardiac transthyretin-related amyloidosis: a bivariate meta-analysis	Meta-analysis of six selected studies on bone scintigraphy in cardiac ATTR including 529 patients provided following results: sensitivity 92.2% (95% CI 89–95%), specificity 95.4% (95% CI 77–99%), LR+ 7.02 (95% CI 3.42–14.4), LR–0.09 (95% CI 0.06–0.14), and DOR 81.6 (95% CI 44–153).	<a href="https://link.springer.com/article/10.1007%2Fs00259-018-4013-4">https://link.springer.com/article/10.1007%2Fs00259-018-4013-4</a>	2018
52.	Observational	Tc-HDP quantitative SPECT/CT in transthyretin cardiac amyloid and the development of a reference interval for myocardial uptake in the non-affected population	HDP thoracic xSPECT/CT QUANT (xQUANT) was performed in 29 patients: ATTR cardiac amyloid (n = 6); AL cardiac amyloid (n = 1); other infiltrative myocardial disease (n = 4); no known infiltrative cardiac disease (n = 18).	<a href="https://doi.org/10.1186/s41824-018-0035-1">https://doi.org/10.1186/s41824-018-0035-1</a>	2018

-	Type of study design*	Title of journal article or research project (including any trial identifier or study lead if relevant)	Short description of research (max 50 words)**	Website link to journal article or research (if available)	Date of publication***
53.	Observational	Semi-quantitative indices of cardiac uptake in patients with suspected cardiac amyloidosis undergoing <sup>99m</sup> Tc-HMDP scintigraphy	Scintigraphy of 76 patients (53 ATTR, 12 AL, 11 LVH) who underwent diagnostic were reviewed. ROC-curve analysis was performed to identify optimal cut-off and relative diagnostic accuracy of six different indices, both in identifying CA patients and in discriminating patients according to their Perugini score.	<a href="https://link.springer.com/article/10.1007%2Fs12350-019-01643-w">https://link.springer.com/article/10.1007%2Fs12350-019-01643-w</a>	2019

\* Categorise study design, for example meta-analysis, randomised trials, non-randomised trial or observational study, study of diagnostic accuracy, etc.

\*\*Provide high level information including population numbers and whether patients are being recruited or in post-recruitment, including providing the trial registration number to allow for tracking purposes.

\*\*\* If the publication is a follow-up to an initial publication, please advise.

Abbreviations and explanations: AC, amyloid cardiomyopathy; AL, amyloid light-chain; ATTR, transthyretin amyloidosis; ATTR-CA, cardiac transthyretin amyloidosis; ATTR-FAP, transthyretin familial amyloid polyneuropathy; ATTRmt, hereditary ATTR; ATTRwt, wild-type amyloidosis; CA, cardiac amyloidosis; CMR, cardiac magnetic resonance; DPD, <sup>99m</sup>Tc-3,3-diphosphono-1,2-propanodicarboxylic acid; E/E' (E/Ea), ratio of mitral peak velocity of early filling (E) to early diastolic mitral annular velocity; EMB, endomyocardial biopsy; FAP, familial amyloid polyneuropathy; GLS, global longitudinal strain; H/CL, heart-to-contralateral; HMDP, <sup>99m</sup>Tc-hydroxymethylene diphosphonate; HRI, heart retention index; H:WB, heart to whole body ratio; LS, longitudinal strain; LV, left ventricle/ventricular; LV-EF, left ventricular ejection fraction; LVH, left ventricular hypertrophy; Mc, maximum accumulation; MDP, <sup>99m</sup>Tc-methylene diphosphonate; MGUS, monoclonal gammopathy of uncertain significance; m-TTR/TTR-m, mutated TTR; MTU, myocardial tracer uptake; Perugini score, score of cardiac uptake of radioactive tracer; PYP, <sup>99m</sup>Tc-pyrophosphate; SPECT, Single-photon emission computed tomography; SPECT/CT, Single-photon emission computed tomography and computed tomography; SSA, senile systemic amyloidosis; TAVI, transcatheter aortic valve implantation; TTR, transthyretin; TTR-CA/TTR-AC, transthyretin cardiac amyloidosis; TTR-CM, transthyretin cardiac amyloidosis; wt-, wild-type; wt-TTR/TTR-wt, wild-type transthyretin amyloidosis

**18. Identify yet to be published research that may have results available in the near future that could be relevant in the consideration of your application by MSAC (limiting these to the English language only). Please do not attach full text articles, this is just intended to be a summary.**

	Type of study design*	Title of research (including any trial identifier if relevant)	Short description of research (max 50 words)**	Website link to research (if available)	Date***
1.	Observational	Pyrophosphate (PYP), and hydroxymethylene diphosphonate (HDP) are reliable and readily available tracers for use in bone scintigraphy for the diagnosis of transthyretin cardiac amyloidosis (TTR)	69 patients diagnosed with TTR underwent bone scintigraphy (tracers were: HDP: 61; PYP: 6; DPD: 1; MDP: 1). 65 demonstrated cardiac uptake. Negative scan patients were as follows: <ul style="list-style-type: none"> <li>• Met30 mutation and asymptomatic carrier;</li> <li>• Normal ECG and biopsy-proven gastrointestinal disease;</li> <li>• Normal cardiac biomarkers and biopsy-proven bladder disease;</li> <li>• False negative with MDP</li> </ul>	Not available. Submitted to CSANZ.	2019

\* Categorise study design, for example meta-analysis, randomised trials, non-randomised trial or observational study, study of diagnostic accuracy, etc.

\*\*Provide high level information including population numbers and whether patients are being recruited or in post-recruitment.

\*\*\*Date of when results will be made available (to the best of your knowledge).

## PART 5 – CLINICAL ENDORSEMENT AND CONSUMER INFORMATION

**19. List all appropriate professional bodies / organisations representing the group(s) of health professionals who provide the service (please attach a statement of clinical relevance from each group nominated):**

Australasian Association of Nuclear Medicine Specialists (AANMS)\*

Australian Amyloidosis Network\*

\*This application has been discussed with, and provided to, the above professional bodies who have undertaken to provide statements of clinical relevance. However, they have not been received and will be forwarded once received.

**20. List any professional bodies / organisations that may be impacted by this medical service (i.e. those who provide the comparator service):**

N/A

**21. List the relevant consumer organisations relevant to the proposed medical service (please attach a letter of support for each consumer organisation nominated):**

There are currently no consumer organisations of relevance to this application as there are no groups representing this patient population with the exception of:

- The Adam Gardiner Foundation who assists the WAC with fundraising (<http://www.agf.org.au/westmead-foundation/>),
- Amyloidosis Australia who provide information for patients and families (<http://www.amyloidosis.com.au/>), and
- The Leukaemia Foundation who provides support particularly for patients with AL amyloidosis.

**22. List the relevant sponsor(s) and / or manufacturer(s) who produce similar products relevant to the proposed medical service:**

N/A

**23. Nominate two experts who could be approached about the proposed medical service and the current clinical management of the service(s):**

**Name of expert 1:** REDACTED

Telephone number(s): REDACTED

Email address: REDACTED

**Name of expert 2:** REDACTED

Telephone number(s): REDACTED

Email address: REDACTED

**Name of expert 3:** REDACTED

Telephone number(s): REDACTED

Email address: REDACTED

## PART 6 – POPULATION (AND PRIOR TESTS), INDICATION, COMPARATOR, OUTCOME (PICO)

### **PART 6a – INFORMATION ABOUT THE PROPOSED POPULATION**

#### **24. Define the medical condition, including providing information on the natural history of the condition and a high level summary of associated burden of disease in terms of both morbidity and mortality:**

The amyloidoses are a rare group of diseases that result from extracellular deposition in organs and tissues of pathologic insoluble fibrillar proteins that self-assemble with highly ordered abnormal cross  $\beta$ -sheet conformation.<sup>6</sup> Fibrillar material derives from various precursor proteins and the classification of amyloidosis is based on the nature of the precursor plasma proteins that form the fibril deposits.<sup>7</sup>

Transthyretin cardiac amyloidosis (ATTR-CM) is a form of cardiac amyloidosis which in turn is a rare form of restrictive cardiomyopathy. The causative amyloid fibril deposits are transthyretin (ATTR) types and this condition is differentiated from monoclonal light chain (AL).<sup>8</sup>

Transthyretin (TTR) is a highly conserved tetrameric protein rich in  $\beta$  strands that is present in all human serum. It is mainly synthesised by the liver, which is the source of 90% of TTR in plasma where its concentration ranges from 20 to 40 mg/DL.<sup>9</sup> TTR's physiological function has been mainly recognised as transportation of thyroid hormones and retinol in plasma.<sup>10</sup> TTR has an innate ability to aggregate into insoluble fibrillar proteins and single point mutations can increase this likelihood leading to subsequent amyloid deposits in the heart, nerves and other tissues. More than 80 TTR amyloidogenic point mutations have been described so far.<sup>11</sup> Inheritance is autosomal dominant with variable penetrance. Some mutations are associated with cardiac involvement, either predominant or associated with peripheral neuropathy, causing familial amyloid cardiomyopathy and familial amyloid polyneuropathy. Wild-type (wt)-non-mutated-TTR can also misfold into the amyloid configuration with almost exclusive deposits in the heart. Consequently, cardiac amyloidosis (CA) is the predominant manifestation in wt-TTR, previously defined as senile CA, which is an age-related disease. Indeed, deposition of the wt protein occurs almost exclusively in men > 60 years of age.<sup>12,13</sup> Whether TTR-related amyloidosis is acquired or hereditary, cardiac involvement has major clinical implications and is strongly associated with mortality.<sup>14</sup>

The cardiac features of cardiac amyloidosis differ according to the stages of diseases.<sup>15</sup> The first phase begins with a subclinical stage characterised by mild and unspecific cardiac symptoms. In this phase, amyloid deposition can involve atria, atrioventricular valves, mild left ventricular (LV) wall thickness (< 15 mm), mild diastolic dysfunction, and mild impaired LV longitudinal strain.

The typical clinical scenario ('hypertrophic' stage), in the fully developed disease, is characterised by a marked thickening of the LV wall (> 15mm) and congestive heart failure with preserved ejection fraction (EF) with a restrictive diastolic pattern with nonspecific symptoms including weakness, fatigue, weight loss or weight gain, and shortness of breath.

<sup>6</sup> Wechalekar AD, Gillmore JD, Hawkins PN. Systemic amyloidosis. *Lancet*, 2016; 387:2641–54.

<sup>7</sup> Sipe JD, Benson MD, Buxbaum JN, et al. Amyloid fibril proteins and amyloidosis: chemical identification and clinical classification. *International Society of Amyloidosis 2016 Nomenclature Guidelines*. *Amyloid* 2016; 23:209–13.

<sup>8</sup> Gilmore JD, Mauer MS, Falk RH, Merlini G, Damy T et al. Nonbiopsy diagnosis of cardiac transthyretin amyloidosis. *Circulation*, 2016; 133:2404-2412.

<sup>9</sup> Vieira M, Saraiva MJ. Transthyretin: a multifaceted protein. *Biomol Concepts*, 2014; 5:45–54.

<sup>10</sup> Ibid

<sup>11</sup> Gertz MA, Benson MD, Dyck PJ, et al. Diagnosis, prognosis and therapy of transthyretin amyloidosis. *J Am Coll Cardiol*, 2015; 66: 2451–66.

<sup>12</sup> Coelho T, Maurer MS, Suhr OB. THAOS - the transthyretin amyloidosis outcomes survey: initial report on clinical manifestations in patients with hereditary and wild-type transthyretin amyloidosis. *Curr Med Res Opin*, 2013;29:63–76

<sup>13</sup> Mohammed SF, Mirzoyev SA, Edwards WD, et al. Left ventricular amyloid deposition in patients with heart failure and preserved ejection fraction. *JACC Heart Fail*, 2014;2:113–22

<sup>14</sup> Damy T, Jaccard A, Guellich A, et al. Identification of prognostic markers in transthyretin and AL cardiac amyloidosis. *Amyloid*, 2016; 23: 194–202.

<sup>15</sup> Di Nunzio D, Recupero A, de Gregorio C, Zito C, Carer S and Di Bella G. Echocardiographic findings in cardiac amyloidosis: inside two-dimensional, doppler, and strain imaging. *Curr Cardiol Rep*, 2019; 21:7

Progressively, in the advanced phase of the disease, biventricular systolic function deteriorates, and symptoms of heart failure become refractory to medical therapy (end-stage phase). In most cases, death occurs from electromechanical dissociation or arrhythmia.

**25. Specify any characteristics of patients with the medical condition, or suspected of, who are proposed to be eligible for the proposed medical service, including any details of how a patient would be investigated, managed and referred within the Australian health care system in the lead up to being considered eligible for the service:**

Amyloid cardiomyopathy should be suspected in patients with heart failure and preserved ejection fraction. Findings of right-sided heart failure predominate, including lower-extremity oedema, hepatomegaly, ascites, and elevated jugular pressure. Right ventricular dilation is linked to more severe cardiac involvement and short survival (median 4 months).<sup>16</sup> Using strain echocardiography, left atrial dysfunction was identified in 32% (lateral left atrial criteria) and 60% (septal left atrial criteria) of patients with amyloidosis.<sup>17</sup> Severe atrial and ventricular infiltration by amyloid may result in mechanical atrial standstill, with resultant thrombus formation.<sup>18</sup>

In addition to heart failure, patients may present with atrial arrhythmias or conduction system disease. In patients who have ventricular thickening without a history of hypertension or valvular disease, an infiltrative cardiomyopathy should be considered.<sup>19</sup> Deposition of amyloid in the myocardial wall causes diastolic dysfunction, restrictive physiology with late loss of systolic function, arrhythmias, and heart failure.<sup>20</sup> The finding of increased wall thickness, small ventricular volume, and occasional dynamic left ventricular outflow tract obstruction can be confused with true hypertrophic conditions such as hypertrophic cardiomyopathy and hypertensive heart disease. Although the electrocardiogram classically shows low voltage in the QRS complex in amyloidosis and increased voltage in myocyte hypertrophy disorders, the overlap is great; voltage can be useful but is not reliable.<sup>21,22</sup>

Clues to the presence of amyloid cardiomyopathy are seen in the widespread deposition of amyloid. In patients with wild-type (wt) ATTR, one-half have associated carpal tunnel syndrome caused by deposition of TTR amyloid into the carpal tenosynovial tissue, with hand symptoms typically preceding cardiac manifestations by 8 to 10 years. Of patients with idiopathic carpal tunnel syndrome, 34% will have amyloid deposition in tenosynovial tissue, possibly representing an early symptom of wt ATTR cardiomyopathy.<sup>23</sup>

Clinical presentation of mutant ATTR is variable and driven by the specific mutation, of which w110 have been described. Patients with mutant ATTR present on a spectrum from exclusive neuropathy to cardiomyopathy-overlapping phenotypes. Among 611 symptomatic patients with hereditary TTR, multisystem involvement was seen with each mutation.<sup>24</sup>

---

<sup>16</sup>Patel AR, Dubrey SW, Mendes LA, et al. Right ventricular dilation in primary amyloidosis: an independent predictor of survival. *Am J Cardiol*,1997;80:486–92.

<sup>17</sup>Modesto KM, Dispenzieri A, Cauduro SA, et al. Left atrial myopathy in cardiac amyloidosis: implications of novel echocardiographic techniques. *Eur Heart J* 2005;26:173–9.

<sup>18</sup>Nakagawa M, Tojo K, Sekijima Y, et al. Arterial thromboembolism in senile systemic amyloidosis: report of two cases. *Amyloid* 2012;19:118–21

<sup>19</sup>Gertz MA, Dispenzieri A, Sher T. Pathophysiology and treatment of cardiac amyloidosis. *Nat Rev Cardiol* 2015;12:91–102.

<sup>20</sup>Castaño A, Drachman BM, Judge D, et al. Natural history and therapy of TTR-cardiac amyloidosis: emerging disease-modifying therapies from organ transplantation to stabilizer and silencer drugs. *Heart Fail Rev* 2015; 20:163–78.

<sup>21</sup>Seward JB, Casaclang-Verzosa G. Infiltrative cardiovascular diseases: cardiomyopathies that look alike. *J Am Coll Cardiol* 2010;55:1769–79.

<sup>22</sup>Rapezzi C, Merlini G, Quarta CC, et al. Systemic cardiac amyloidoses: disease profiles and clinical courses of the 3 main types. *Circulation* 2009;120: 1203–12

<sup>23</sup>Sekijima Y, Uchiyama S, Tojo K, et al. High prevalence of wild-type transthyretin deposition in patients with idiopathic carpal tunnel syndrome: a common cause of carpal tunnel syndrome in the elderly. *Hum Pathol*, 2011; 42:1785–91.

<sup>24</sup>Coelho T, Maurer MS, Suhr OB. THAOS: The Transthyretin Amyloidosis Outcomes Survey: initial report on clinical manifestations in patients with hereditary and wild-type transthyretin amyloidosis. *Curr Med Res Opin* 2013;29:63–76.

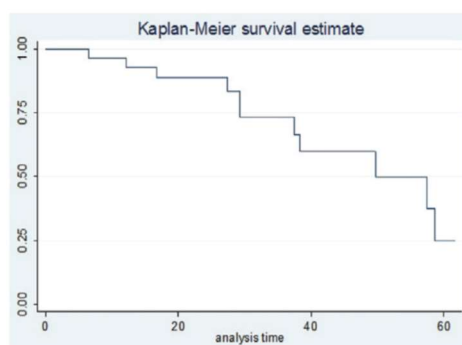
### **Australian Registry (Queensland)<sup>25</sup>**

Patients were those with a diagnosis of ATTRwt referred to the Hospital Amyloidosis Centre from 2011–2016. Biochemical, clinical, and survival data were recorded. Findings were compared with a small sample of 7 patients with hereditary ATTR (ATTR-mut).

35 patients with ATTRwt were analysed, with mean age 77 years (range: 60–88 years), all of whom were male. The cohort had a mean elevated troponin I (0.08ng/L; range: 0.01–0.147) and BNP (360pg/ml; range: 50–1370) at diagnosis.

Monoclonal gammopathy of uncertain significance, with an elevated serum paraprotein on electrophoresis, was present in 25% of cases. Electrocardiography revealed a high prevalence of atrial fibrillation (37.5%) and conduction disease (bundle branch block in 20% of patients; PPM 15%). Baseline echocardiographic parameters included a significantly elevated left ventricular mass index (LVMI) (mean 148g/m<sup>2</sup>), with 75% of patients having a left ventricular wall thickness >1.1cm (mean 1.6 cm) and 92% a right ventricular wall thickness >0.6cm (mean 1.0cm). Left ventricular ejection fraction was mildly reduced at time of diagnosis (mean LVEF 47.7%; range: 21–65%), with 40% of patients having an LVEF <40%. Global longitudinal strain was markedly impaired (mean GLS -9.8%; range: -5.2, -18.8) with characteristic apical sparing in 80% of patients. 80% of patients had an E/E' >12 with significant left atrial enlargement (mean LA volume 55.7ml/m<sup>2</sup>).

DPD scintigraphy was positive in 100% of patients with cardiac ATTRwt. 60% of patients were in advanced Mayo Stage 3 at diagnosis. 4-year overall survival was 60% (95% CI: 34–78%) with median overall survival 49.7 months (see Kaplan Meier Survival Curve). When compared to patients with ATTRmut, the group with ATTRwt was older, exclusively male, and had more advanced disease (on echocardiography and cardiac biomarkers).



Kaplan-Meier Survival in ATTRwt

### **Melbourne Amyloidosis Centre (2018)<sup>26</sup>**

The experience at the Victorian and Tasmanian Amyloidosis Service was audited. Fifty-two patients (51 male, one female) were diagnosed with wild-type TTR from September 2014 to January 2018. Cardiac biopsy confirmed TTR in 18, and biopsies from other sites confirmed it in eight. All had suggestive echocardiograms and 48 underwent bone scintigraphy, all demonstrating cardiac uptake (Perugini score 3, 2, and 1 seen in 22, 24, and 2, respectively). Genetic screening in nine patients confirmed wild-type (non-hereditary) disease. Thirty-seven (71%) had carpal tunnel syndrome and eight (15%) had coexisting plasma-cell dyscrasiae. Using Gillmore staging (N-terminal pro b-type natriuretic peptide and estimated glomerular filtration rate), 24 (46%) were stage 1, 20 (38%) stage 2, and eight (15%) stage 3. At a median of 12 months follow-up (range 1–41), eight (15%) patients died: five stage 2 and three stage 3.

<sup>25</sup>Burrage N, Korczyk D, Mollee P. First Australian registry of patients with wild type cardiac amyloidosis (ATTRwt): Queensland experience. *European Heart Journal*, 2017; 38 (Supplement 1) p.405

<sup>26</sup>Lasica M, Ting S, Cooke J, Wong C, Slocombe A, Zimmet H, Hosking P, Hare J and Gibbs S. Cardiac Transthyretin Amyloidosis: Are we under-diagnosing and under-treating? [https://www.heartlungcirc.org/article/S1443-9506\(18\)30819-9/pdf](https://www.heartlungcirc.org/article/S1443-9506(18)30819-9/pdf)



### **Melbourne Amyloidosis Centre (2018)<sup>27</sup>**

69 patients diagnosed with TTR underwent bone scintigraphy. TTR was confirmed on direct biopsy in 25, including 12 cardiac; and/or genetic studies confirming TTR mutations in 5; and/or on clinical phenotype (older male with isolated HFpEF +/- carpal tunnel releases), with echocardiographic features (IVSD >12mm) and elevated cardiac biomarkers in 57. Six underwent bone marrow biopsies demonstrating <5% plasma cells and Congo red negative, thus AL was excluded. All but one had normal serum free light chain (SFLC) ratios. Cardiac MRI confirmed amyloidosis in 25.

Tracers used were: HDP in 61, PYP in 6, and 1 each for DPD and MDP. 65 demonstrated cardiac uptake. For negative scan patients, one had normal cardiac biomarkers with no clinical evidence of amyloidosis but positive for Met30 mutation, thus deemed an asymptomatic carrier; another had normal echocardiography with isolated biopsy-proven gastrointestinal disease; another had isolated biopsy-proven bladder disease with normal cardiac biomarkers. The final patient had bone scintigraphy using methylenediphosphonate (MDP), which was falsely negative. MDP is not validated for detecting cardiac amyloidosis.

### **26. Define and summarise the current clinical management pathway *before* patients would be eligible for the proposed medical service (supplement this summary with an easy to follow flowchart [as an attachment to the Application Form] depicting the current clinical management pathway up to this point):**

Historically, endomyocardial biopsy was the gold standard in investigations for cardiac amyloidosis. Due to the risk and invasiveness of this procedure, particularly in a population of patients who are elderly, it has recently been reserved for cases when a conclusive diagnosis cannot be made with less invasive procedures.

Radionuclide scintigraphy with <sup>99m</sup>Tc-labeled pyrophosphate (PYP), <sup>99m</sup>Tc-labeled oxidronate (HDP) and <sup>99m</sup>Tc-labeled 3,3-diphosphono-1,2-propanodicarboxylic acid (DPD) are sensitive and specific for imaging cardiac ATTR amyloid and enables a diagnosis of TTR-CM.

Scintigraphy is now used in amyloid centres for the diagnosis of cardiac amyloidosis from TTR-CM. However, this method of diagnosis is not well known outside of these centres.

Tafamidis (**REDACTED**) will be the first treatment specifically available for the treatment of this condition once registered by the TGA and the availability of the treatment will increase the use of scintigraphy for diagnosis.

#### Patients with cardiomyopathy

The steps in the algorithm are as follows:

- Patients with signs and symptoms suggestive of TTR-CM:
  - 1) ≥65 years old;
  - 2) usually male;
  - 3) heart failure;
  - 4) Echocardiographic features:
    - increased left ventricular wall thickness (≥12 mm)
    - restrictive cardiac filling pattern
    - abnormal left and right ventricular longitudinal strain, and
    - atrial septal thickening.
  - 5) preserved ejection fraction (in most cases);
  - 6) often had prior carpal tunnel syndrome;
  - 7) raised levels of NT-pro-BPN and troponin I
- The following diagnostic tests are performed:

---

<sup>27</sup> Wong C, Lasica M, Hare J, Saddik D, Hocking J, Slocombe A, Cooke J, Ting S and Gibbs S. Pyrophosphate (PYP), and hydroxymethylene diphosphonate (HDP) are reliable and readily available tracers for use in bone scintigraphy for the diagnosis of transthyretin cardiac amyloidosis (TTR).

	Scintigraphy available	Scintigraphy not available
1)	Cardiac scintigraphy	Endomyocardial biopsy followed by immunohistochemistry ± mass spectrometry
2)	Serum protein electrophoresis and serum free light chain assay (presence of monoclonal protein) [The tests are available on the MBS: serum or urine protein electrophoresis, 71057; serum or urine immunofixation, 71059; and serum free light chains 71200]	Serum protein electrophoresis and serum free light chain assay (presence of monoclonal protein) [The tests are available on the MBS: serum or urine protein electrophoresis, 71057; serum or urine immunofixation, 71059; and serum free light chains 71200]
3)	In the following situations, endomyocardial biopsy followed by immunohistochemistry ± mass spectrometry is performed: Grade on scintigraphy Monoclonal protein 0 (scintigraphy) and positive (protein) 1 (scintigraphy) and positive or negative (protein) 2 to 3 (scintigraphy) and positive (protein)	N/A

### Diagnosis

#### Scintigraphy available

Where the grade on scintigraphy is 0 and monoclonal protein is negative, a diagnosis of cardiac amyloidosis is unlikely. Where the grade on scintigraphy is 2-3 and monoclonal protein is negative, a diagnosis of cardiac ATTR amyloidosis can be made. Where the grade on scintigraphy is 1 and monoclonal protein is either positive or negative, histological confirmation by biopsy will allow a diagnosis of AL, apolipoprotein A-I (AApoA), ATTR or other.

#### Scintigraphy not available

Biopsy will allow a diagnosis of AL, apolipoprotein A-I (AApoA), ATTR or other.

#### Patients with TTR amyloidosis presenting with cardiac symptoms

In patients who have been diagnosed with TTR amyloidosis which has deposited in other areas and who present with cardiac symptoms, the following tests will be performed:

- Echocardiography,
- NT-pro-BPN and troponin I, and
- cardiac scintigraphy or endomyocardial biopsy depending on availability.

Patients who present with grade 2-3 on scintigraphy will be diagnosed with ATTR-CM. Where patients have grade 0 or 1 on scintigraphy, further diagnosis is necessary. Where cardiac scintigraphy is not available, the diagnosis will be made based on the endomyocardial biopsy.

Flowcharts of current and proposed clinical management pathways are provided.

## **PART 6b – INFORMATION ABOUT THE INTERVENTION**

### **27. Describe the key components and clinical steps involved in delivering the proposed medical service:<sup>28</sup>**

- a) PYP, HDP or DPD administered to patient
- b) Whole body scans 5 minutes and 3 hours after injection
- c) Heart retention, whole-body retention and heart to whole-body retention ratios semi-quantitatively analysed using early whole-body counts to represent the injected activity
- d) Visual scoring of cardiac retention performed on the basis of late images

#### Nuclear imaging studies

The type of imaging study performed depends on the centre, the preferences of the nuclear medicine specialist/cardiologist and the equipment available. These include:

#### Planar imaging

Planar imaging uses radiotracers that generate gamma decay which generates one photon in random direction at a time. Therefore, these photons are captured in one direction only, similar to X-ray, but using gamma rays emitted from the patient. The images are taken using a gamma camera and are 2 D images like plain films in X-ray imaging.

Planar imaging is used in standard bone scanning and assessment of ATTR. It has a role at the bedside of acutely ill patients, or instrumented patients, where imaging can only be performed using planar imaging technique and portable gamma cameras. It is also used in centres where SPECT and SPECT/CT facilities are unavailable.

In bone scanning and ATTR imaging, planar imaging can be performed of a limited region (e.g. thorax alone, including the heart) or of the whole body (looking at the entire skeleton). Given ATTR is a systemic disease whole body images provide a better assessment of the extent of disease involvement. This is recognised in the usual scoring system most widely used in assessing bone scanning in ATTR.

#### Single photon emission computed tomography (SPECT)

SPECT uses radiotracers that generate gamma decay and captures photons in multiple directions, similar to X-ray CT. It uses a gamma camera just like conventional planar nuclear medicine imaging but creates 3D datasets and images. The gamma camera acquires data from multiple angles around the patient. SPECT shows function of an organ (e.g. blood flow to the heart) in 3D avoiding misinterpretation due to overlap with other structures (e.g. ribs or spine overlapping heart on planar imaging for ATTR).

#### Single photon emission computed tomography/computed tomography (SPECT/CT)

Nuclear medicine uses a gamma camera to measure gamma rays emitted by the tracer. These gamma rays are attenuated by the deeper body tissues, which could lead to a significant underestimation of activity from areas deeper in the body. SPECT/CT uses the x-ray attenuation information from computed tomography to correct for SPECT attenuation, which is important for accurate 3D signal measurement. In addition, SPECT/CT provides the ability to overlay the functional data from SPECT (e.g. HDP uptake in ATTR cardiac disease) with the anatomic data from CT (allowing precise localisation to left ventricle, RV free wall or atrium).

#### Interpretation of images

Image interpretation will depend on the agent used, the type of imaging and the preferences of the Nuclear Medicine Specialist interpreting the images. Techniques used vary from a semiquantitative grading score to a semi-quantitative measure of heart-to-whole body or heart-to-contralateral lung uptake ratio (H/CL) or more recently absolute measurement of the concentration of radioactivity within the myocardium.<sup>29</sup>

---

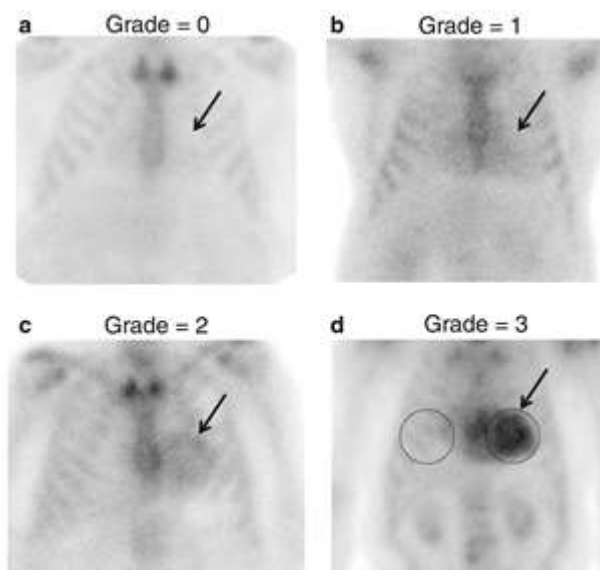
<sup>28</sup> Lairez O, Pascal P, Victor G, Bastié D, Lavie-Badie Y, Pierre A, Cassol E and Berry I. Bone scintigraphy for cardiac amyloidosis imaging: Past, present and future. *Médecine Nucléaire*, 2017; 41:108–114.

<sup>29</sup> Ramsay SC, Lindsay K, Fong W et al. Tc-HDP quantitative SPECT/CT in transthyretin cardiac amyloid and the development of a reference interval for myocardial uptake in the non-affected population. *Eur J Hybrid Imaging*. 2018; 2(1): 17.

The semi-quantitative scoring system, first proposed by Perugini et al.<sup>30</sup>, uses a grading system based on assessing relative uptake in the myocardium and in the bone. There are a number of closely related interpretations but on the whole, they can be summarised as: grade 0 = absent cardiac uptake; grade 1 = mild uptake less than bone; grade 2 = moderate uptake equal to bone; grade 3 = high uptake greater than bone with associated reduced uptake in bone. As indicated by Gilmore et al.<sup>31</sup>, cardiac ATTR amyloidosis can be reliably diagnosed in the absence of histology provided that all of the following criteria are met: heart failure with an echocardiogram or cardiac magnetic resonance that is consistent with or suggestive of amyloidosis, grade 2 or 3 cardiac uptake on a radionuclide scan with <sup>99m</sup>Tc-DPD, <sup>99m</sup>Tc-PYP, or <sup>99m</sup>Tc-HMDP, and absence of a detectable monoclonal protein despite serum IFE, urine IFE, and sFLC (Freelite) assay.

The quantitative H/CL ratio, on the other hand, is calculated by dividing counts from a region of interest (ROI) over the heart to those of the same region on the contralateral chest wall defined as “background”.  $H/CL \geq 1.6$  based on 1-h delayed image acquisition has been frequently used to define “positive” for TTR cardiac amyloidosis.

Two figures to show the interpretation are shown below.

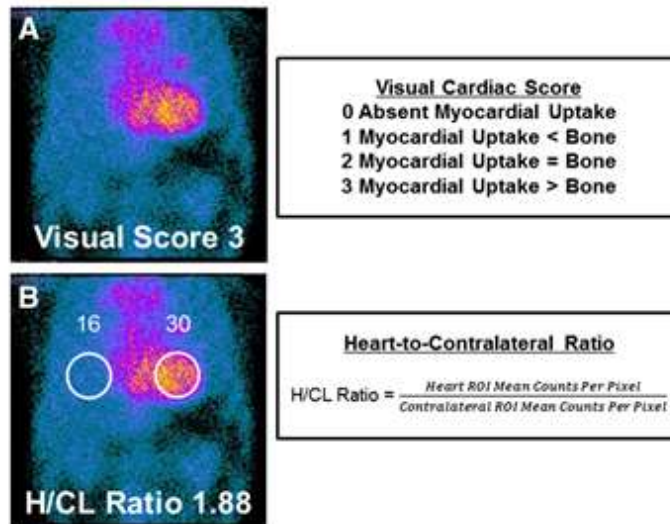


Representative images of <sup>99m</sup>Tc-PYP uptake in TTR cardiac amyloidosis patients. a) non visualisation of cardiac uptake in an HFpEF patient without TTR involvement (arrow points to the cardiac region), grade = 0, b) mild uptake less than bone, grade = 1, c) moderate uptake equal to bone, grade 2; d) high uptake greater than bone, grade = 3. The circles represent region of interest in the cardiac area and contralateral right chest wall for quantitative analysis. The H/CL was calculated by dividing counts from the left to those of the same region on the contralateral chest wall.<sup>32</sup>

<sup>30</sup> Perugini E, Guidalotti PL, Salvi F, Cooke RMT, Pettinato C, Riva L, et al. Noninvasive etiologic diagnosis of cardiac amyloidosis using <sup>99m</sup>Tc-3,3-diphosphono-1,2-propanodicarboxylic acid scintigraphy. *J Am Coll Cardiol.* 2005; 46:1076–8

<sup>31</sup> Gillmore JD, Maurer MS, Falk RH, Merlini G, Damy T, Dispenzieri A, et al. Nonbiopsy diagnosis of cardiac transthyretin amyloidosis. *Circulation.* 2016;133(24):2404–2412. doi: 10.1161/CIRCULATIONAHA.116.021612.

<sup>32</sup> Chen W, Ton V-K and Dilsizian V. Clinical phenotyping of transthyretin cardiac amyloidosis with bone-seeking radiotracers in heart failure with preserved ejection fraction. *Current Cardiology Reports,* 2018; 20: 23



Semiquantitative and quantitative analysis of <sup>99m</sup>Tc-PYP myocardial uptake. Semiquantitative analysis (A): visual cardiac score, which was assigned 0–3 according to the scale detailed. The representative image demonstrates a visual cardiac score of 3. Quantitative analysis (B): heart-to-contralateral ratio was calculated by drawing a region of interest over the heart, copying and mirroring it to the contralateral chest and calculating the ratio of heart ROI mean counts to contralateral ROI mean counts.<sup>33</sup>

**28. Does the proposed medical service include a registered trademark component with characteristics that distinguishes it from other similar health components?**

Radiopharmaceuticals may have trademarks.

Co-dependent treatment of TTR-CM, **REDACTED** (tafamidis), has a trade mark.

**29. If the proposed medical service has a prosthesis or device component to it, does it involve a new approach towards managing a particular sub-group of the population with the specific medical condition?**

N/A

**30. If applicable, are there any limitations on the provision of the proposed medical service delivered to the patient (i.e. accessibility, dosage, quantity, duration or frequency):**

N/A

**31. If applicable, identify any healthcare resources or other medical services that would need to be delivered at the same time as the proposed medical service:**

Serum protein electrophoresis and serum free light chain assay to differentiate AL

**32. If applicable, advise which health professionals will primarily deliver the proposed service:**

Administration of radiopharmaceuticals in Australia is a state responsibility and radiation laws vary from state to state. In Queensland a nuclear medicine trained doctor must prescribe radiopharmaceuticals for administration to humans, but they can be administered by a person with an appropriate licence. This can be a doctor, a nuclear medicine scientist (i.e. a technologist), or another appropriately trained health care worker who has been credentialed in this area e.g. a registered nurse or a medical physicist. This is different in other states.

Clause 2.4.1 of the Health Insurance (Diagnostic Imaging Services Table) Regulations requires that all Medicare-eligible nuclear medicine services must be performed by or under the supervision of a specialist or consultant physician who is credentialed by the Joint Nuclear Medicine Credentialing and Accreditation Committee, the specialist must personally examine the patient, estimate and administer the radiopharmaceutical, and prepare the report.

<sup>33</sup> Castañó A, DeLuca A, Weinberg R, Pozniakoff T, Blaner WS, Pirmohamed A, Bettencourt B, Gollob J, Karsten V, Vest JA, Chiuzaan C, Maurer MS and Bokhari S. Serial scanning with technetium pyrophosphate (99mTc-PYP) in advanced ATTR cardiac amyloidosis. *Journal of Nuclear Cardiology*, 2016; 1355-1363.

**33. If applicable, advise whether the proposed medical service could be delegated or referred to another professional for delivery:**

See 32. above.

**34. If applicable, specify any proposed limitations on who might deliver the proposed medical service, or who might provide a referral for it:**

Not applicable

**35. If applicable, advise what type of training or qualifications would be required to perform the proposed service as well as any accreditation requirements to support service delivery:**

See 32. above.

**36. (a) Indicate the proposed setting(s) in which the proposed medical service will be delivered (select all relevant settings):**

- Inpatient private hospital
- Inpatient public hospital
- Outpatient clinic
- Emergency Department
- Consulting rooms
- Day surgery centre
- Residential aged care facility
- Patient's home
- Laboratory
- Other – please specify below

Nuclear medicine departments associated with the above.

**(b) Where the proposed medical service is provided in more than one setting, please describe the rationale related to each:**

This is dependent on where the patient is seen. They are likely to be referred to a nuclear medicine department associated with the hospital or a private nuclear medicine department.

**37. Is the proposed medical service intended to be entirely rendered in Australia?**

- Yes
- No – please specify below

Specify further details here

**PART 6c – INFORMATION ABOUT THE COMPARATOR(S)**

- 38. Nominate the appropriate comparator(s) for the proposed medical service, i.e. how is the proposed population currently managed in the absence of the proposed medical service being available in the Australian health care system (including identifying health care resources that are needed to be delivered at the same time as the comparator service):**

In the absence of scintigraphy, endomyocardial biopsy would be performed to identify patients with TTR-CM.

- 39. Does the medical service that has been nominated as the comparator have an existing MBS item number(s)?**

- Yes (please provide all relevant MBS item numbers below)  
 No

MBS item number 38275.

- 40. Define and summarise the current clinical management pathways that patients may follow *after* they receive the medical service that has been nominated as the comparator (supplement this summary with an easy to follow flowchart [as an attachment to the Application Form] depicting the current clinical management pathway that patients may follow from the point of receiving the comparator onwards including health care resources):**

As mentioned historically, endomyocardial biopsy was the gold standard in investigations for cardiac amyloidosis. Due to the risk and invasiveness of this procedure, particularly in a population of patients who are elderly, it has recently been reserved for cases when a conclusive diagnosis cannot be made with less invasive procedures.

In the absence of cardiac scintigraphy, the steps in the algorithm are as follows:

- Patients with signs and symptoms suggestive of TTR-CM:
  - 1) ≥65 years old;
  - 2) usually male;
  - 3) heart failure;
  - 4) Echocardiographic features:
    - increased left ventricular wall thickness (≥12 mm)
    - restrictive cardiac filling pattern
    - abnormal left and right ventricular longitudinal strain, and
    - atrial septal thickening.
  - 5) preserved ejection fraction (in most cases);
  - 6) often had prior carpal tunnel syndrome;
  - 7) raised levels of NT-pro-BPN and troponin I
- The following diagnostic tests are performed:
  - 1) Endomyocardial biopsy followed by immunohistochemistry ± mass spectrometry
  - 2) Serum protein electrophoresis and serum free light chain assay (presence of monoclonal protein) [The tests are available on the MBS: serum or urine protein electrophoresis, 71057; serum or urine immunofixation, 71059; and serum free light chains 71200]
- These tests will allow a diagnosis of AL, apolipoprotein A-I (AApoA), ATTR or other.

In patients who have been diagnosed with TTR amyloidosis which has deposited in other areas and who present with cardiac symptoms, the following tests will be performed:

- Echocardiography,
- NT-pro-BPN and troponin I, and
- Endomyocardial biopsy

These tests will allow a diagnosis to be made.

A flowchart of the current clinical management pathway is provided

- 41. (a) Will the proposed medical service be used in addition to, or instead of, the nominated comparator(s)?**

- Yes

No

**(b) If yes, please outline the extent of which the current service/comparator is expected to be substituted:**

In most patients scintigraphy will replace endomyocardial biopsy, however, in patients where the pathology tests for serum protein electrophoresis and serum free light chain assay for AL are positive, an endomyocardial biopsy is required for diagnosis (AL or MGUS). In addition, where, at the discretion of the treating clinician gene testing is warranted endomyocardial biopsy, or biopsy of other sites, is performed.

**42. Define and summarise how current clinical management pathways (from the point of service delivery onwards) are expected to change as a consequence of introducing the proposed medical service including variation in health care resources (Refer to Question 39 as baseline):**

Patients with cardiomyopathy

The steps in the algorithm are as follows:

- Patients with signs and symptoms suggestive of TTR-CM:
  - 8) ≥65 years old;
  - 9) usually male;
  - 10) heart failure;
  - 11) Echocardiographic features:
    - increased left ventricular wall thickness (≥12 mm)
    - restrictive cardiac filling pattern
    - abnormal left and right ventricular longitudinal strain, and
    - atrial septal thickening.
  - 12) preserved ejection fraction (in most cases);
  - 13) often had prior carpal tunnel syndrome;
  - 14) raised levels of NT-pro-BPN and troponin I
- The following diagnostic tests are performed:
  - 1) Cardiac scintigraphy
  - 2) Serum protein electrophoresis and serum free light chain assay (presence of monoclonal protein) [The tests are available on the MBS: serum or urine protein electrophoresis, 71057; serum or urine immunofixation, 71059; and serum free light chains 71200]
  - 3) In the following instances, endomyocardial biopsy followed by immunohistochemistry ± mass spectrometry will be performed:

Grade on scintigraphy	Monoclonal protein
0	Positive
1	Positive or negative
2 to 3	Positive

Where the grade on scintigraphy is 0 and monoclonal protein is negative, a diagnosis of cardiac amyloidosis is unlikely. Where the grade on scintigraphy is 2-3 and monoclonal protein is negative, a diagnosis of cardiac ATTR amyloidosis can be made. Where the grade on scintigraphy is 1 and monoclonal protein is either positive or negative, histological confirmation by biopsy will allow a diagnosis of AL, apolipoprotein A-I (AApoA), ATTR or other.

Patients diagnosed with TTR amyloidosis in other areas

In patients who have been diagnosed with TTR amyloidosis which has deposited in other areas and who present with cardiac symptoms, the following tests will be performed:

- Echocardiography,
- NT-pro-BPN and troponin I, and
- cardiac scintigraphy

Should the results of cardiac scintigraphy be grade 0 or 1, further diagnostic tests will be required.

Flowcharts of current and proposed clinical management pathways are provided.



**PART 6d – INFORMATION ABOUT THE CLINICAL OUTCOME**

**43. Summarise the clinical claims for the proposed medical service against the appropriate comparator(s), in terms of consequences for health outcomes (comparative benefits and harms):**

The overall clinical claim is that the proposed co-dependent technologies (cardiac scintigraphy and tafamidis) are equivalent in terms of comparative effectiveness and superior in terms comparative safety versus the main comparator (endomyocardial biopsy and tafamidis) in eligible patients with TTR-CM.

Note that even in the absence of treatment with tafamidis a confirmed diagnosis of TTR-CM is still important as these patients cannot be treated with standard heart failure treatments e.g. calcium channel and beta-blockers.

**44. Please advise if the overall clinical claim is for:**

- Superiority  
 Non-inferiority

**45. Below, list the key health outcomes (major and minor – prioritising major key health outcomes first) that will need to be specifically measured in assessing the clinical claim of the proposed medical service versus the comparator:**

**Safety Outcomes:**

Test Outcomes:

1. Safety
2. Risks of test

Drug Outcomes (tafamidis):

1. Safety and tolerability
2. Electrocardiograms
3. Clinical laboratory testing
4. Vital signs
5. Physical examinations

**Clinical Effectiveness Outcomes:**

Test Outcomes:

3. Sensitivity
4. Specificity
5. Positive predictive value
6. Negative predictive value
7. Rates of false positives
8. Rates of false negatives
9. Re-testing rates
10. Prognostic value
11. Safety
12. Risks of test

Drug Outcomes (tafamidis):

The primary analysis used a hierarchical combination, applying the method of Finkelstein-Schoenfeld to:

1. All-cause mortality and
2. Frequency of cardiovascular-related hospitalisations over the duration of the trial, which was defined as the number of times a subject was hospitalised (i.e., admitted to a hospital) for cardiovascular-related morbidity.

The key secondary efficacy endpoints were as follows:

1. Change from baseline to Month 30 in the distance walked during 6-Minute Walk Test (6MWT).
2. Change from baseline to Month 30 in the Kansas City Cardiomyopathy Questionnaire (KCCQ) - Overall summary (OS) score.

The secondary endpoints were:

1. Cardiovascular-related mortality.
2. Frequency of cardiovascular-related hospitalization.
3. All-cause mortality.
4. TTR stabilisation at Month 1.

## PART 7 – INFORMATION ABOUT ESTIMATED UTILISATION

### 46. Estimate the prevalence and/or incidence of the proposed population:

As discussed previously, TTR-CM occurs predominantly in males who are ≥65 years old and who have heart failure (HF) with echocardiographic features (increased left ventricular wall thickness, restrictive cardiac filling pattern, abnormal left and right ventricular longitudinal strain, and atrial septal thickening). These patients usually have a preserved ejection fraction (HFpEF) and raised levels of NT-pro-BNP and troponin I. They also often have had prior carpal tunnel syndrome.

#### **Heart failure**

Sahle et al (2016)<sup>34</sup> performed a systematic review of the prevalence of heart failure in Australia. There were no studies reporting the incidence of HF in Australia. According to the AIHW (based on extrapolation of incidence rates from large scale international cohorts to the Australian population characteristics) an estimated 30,000 new cases of HF are diagnosed each year in Australia<sup>35</sup>, which translates into a crude incidence rate of 2.1 per 1000 population. Based on self-report, the prevalence of HF and oedema in adults was estimated to be 1.4 % in the 2004/5, 1.3 % in the 2007/8, and 1.2 % in the 2011/12 National Health Surveys.<sup>36,37,38</sup>

The national population prevalence of HF was reported in four studies, ranging from 1.5–2.0%.<sup>39,40,41,42</sup> Two studies reported the prevalence of chronic conditions among samples of 9156<sup>33</sup> and 8707<sup>34</sup> general practice patients adjusted for the Australian population. In these studies, the prevalence of HF in the population was estimated to be 1.8%<sup>33</sup> and 1.5%<sup>34</sup>, respectively. In the third study, HF data were derived by applying international HF prevalence data to the Australian population<sup>35</sup>. The study reported a national prevalence of 17.9 per 1000<sup>35</sup>. A slightly higher prevalence rate (2.0%) was also reported in a similar study, which extrapolated HF data from Scotland and United Kingdom to the Australian population<sup>36</sup>.

In the Canberra Heart Study, which screened 1,275 people aged 60–86 years old, 6.7% (95 % CI: 4.4 %-7.1 %) of them had HF and 0.6% (95 % CI: 0.3 %-1.2 %) of these were previously undiagnosed<sup>43</sup>. In the same study, the prevalence of HF ranged between 3.1% in those 60–64 years old to 13.6% in those 80–86 years old<sup>37</sup>. In another study, on a sample of 23,845 general practice patients aged 60 years and over, HF was reported in 13.1% of them comprising previously diagnosed cases (prevalence, 11.2%) and newly diagnosed cases (prevalence, 1.9 %).<sup>44</sup> However, this rate was not adjusted for the general population.

In the NHS<sup>30,31,32</sup> HF was almost twice as common in women than in men. Prevalence rates were 0.89% vs 1.8% in the 2004/5 NHS, 1.0% vs 1.7% in the NHS 2007/8 and 1.0% vs 1.5% in the NHS 2011/12 in men and women, respectively.<sup>30,31,32</sup> On the other hand, In the Canberra Heart Study, HF was twice as common in men (8.2%) than in women (4.4%).<sup>45</sup>

<sup>34</sup>Sahle BW, Owen AJ, Mutowo MP, Krum H and Reid CM. Prevalence of heart failure in Australia: a systematic review. *BMC Cardiovascular Disorders*, 2016; 16:32.

<sup>35</sup>AIHW: Field B. Heart failure...what of the future? Bulletin no. 6. AIHW Cat. No. AUS 34. Canberra: AIHW; 2003

<sup>36</sup>Australian Bureau of Statistics, National Health Survey: Summary of results 2004–05. Cat. no. 4364.0.Canberra:ABS;2006.

<sup>37</sup>Australian Bureau of Statistics, National Health Survey: Summary of Results, 2007–2008 (Reissue). Cat. no. 43640DO020\_20072008. Canberra: ABS; 2009.

<sup>38</sup>Australian Bureau of Statistics, National Health Survey: First Results, 2011–12. Cat. no. 43640DO003\_20112012. Canberra: ABS; 2012.

<sup>39</sup>Knox SA, Harrison CM, Britt HC, Henderson J. Estimating prevalence of common chronic morbidities in Australia. *Med J Aust*. 2008; 189:66–70.

<sup>40</sup>Harrison C, Britt H, Miller G, Henderson J. Prevalence of chronic conditions in Australia. *PLoS One*. 2013;8:e67494.

<sup>41</sup>Clark RA, McLennan S, Eckert K, Dawson A, Wilkinson D, Stewart S. Chronic heart failure beyond city limits. *Rural Remote Health*. 2005; 5:443.

<sup>42</sup>Clark RA, McLennan S, Dawson A, Wilkinson D, Stewart S. Uncovering a hidden epidemic: a study of the current burden of heart failure in Australia. *Heart Lung Circ*. 2004; 13:266–73.

<sup>43</sup>Abhayaratna WP, Smith WT, Becker NG, Marwick TH, Jeffery IM, McGill DA. Prevalence of heart failure and systolic ventricular dysfunction in older Australians: the Canberra Heart Study. *Med J Aust*. 2006; 184:151–4.

<sup>44</sup>Clark RA, Eckert KA, Stewart S, Phillips SM, Yallop JJ, Tonkin AM, et al. Rural and urban differentials in primary care management of chronic heart failure: new data from the CASE study. *Med J Aust*. 2007; 186:441–5.

<sup>45</sup>Abhayaratna WP, Smith WT, Becker NG, Marwick TH, Jeffery IM, McGill DA. Prevalence of heart failure and systolic ventricular dysfunction in older Australians: the Canberra Heart Study. *Med J Aust*. 2006; 184:151–4.

**Heart failure with preserved ejection fraction (HFpEF)**

In the Management of Cardiac Failure program in Northern Sydney Australia, HFpEF was reported as 37.4% of total heart failure.<sup>46</sup> In the Acute Heart Failure Global Registry of Standard Treatment (ALARM-HF) including 4,953 patients hospitalised for HF in nine countries in Europe, Latin America, and Australia, HFpEF was reported as 24% of total HF.<sup>47</sup>

Baseline demographic and clinical characteristics of patients in these studies which could be suggestive of TTR-CM occurred at rates shown in the table below.

Baseline characteristics	Management of Cardiac Failure Program <sup>40</sup>	ALARM-HF <sup>41</sup>
Age > 75 years	75.5%	32.5%
Cardiomyopathy	NR	7.7%
Atrial fibrillation	49.9%	45.5%
Chronic kidney disease	19.5%	18.2%
Permanent pacemaker	9.6%	5.2%
Dyspnoea	93.1%	71.8%

**47. Estimate the number of times the proposed medical service(s) would be delivered to a patient per year:**

Cardiac scintigraphy is used for diagnosis. Its efficacy in ongoing monitoring of the condition has not been demonstrated. Therefore, it will not be used more than once i.e. for diagnosis only.

**48. How many years would the proposed medical service(s) be required for the patient?**

Refer to 47 above

**49. Estimate the projected number of patients who will utilise the proposed medical service(s) for the first full year:**

	Year 1	Source
<b>Population</b>		
<b>Males</b>		ABS3222.0 - Population Projections, Australia
65-74 years	1,137,080	
75-84 years	604,297	
≥85 years	199,680	
<b>Females</b>		
65-74 years	1,200,607	
75-84 years	685,616	AIHW 2011 <sup>48</sup>
≥85 years	317,534	
<b>Prevalence</b>		
<b>Males</b>		
65-74 years	3.6%	
75-84 years	6.0%	
≥85 years	8.0%	
<b>Females</b>		
65-74 years	4.8%	
75-84 years	7.0%	
≥85 years	16.8%	
<b>HF</b>		Population projections x incidence rates
<b>Males</b>		

<sup>46</sup> Wang N, Hales S, Barin E and Tofler G. Characteristics and outcome for heart failure patients with mid-range ejection fraction. J Cardiovasc Med 2018, 19:297–303

<sup>47</sup>Farmakis D, Simitis P, Bistola V, Triposkiadis F, Ikonomidis I, Katsanos S, Bakosis G, Hatzigelaki E, Lekakis J, Mebazaa A and Parissis J. Acute heart failure with mid-range left ventricular ejection fraction: clinical profile, in-hospital management, and short-term outcome. Clin Res Cardiol (2017) 106:359–368

<sup>48</sup> AIHW. Cardiovascular Disease. Australia Facts 2011. Figure 6.1

	Year 1	Source
65-74 years	40,935	
75-84 years	36,258	
≥85 years	15,974	
<b>Total</b>	<b>93,167</b>	
<b>Females</b>		
65-74 years	57,629	
75-84 years	47,993	
≥85 years	53,346	
<b>Total</b>	<b>158,968</b>	
<b>HFpEF</b>		
HFpEF	37%	Wang 2018 <sup>49</sup>
<b>Males</b>	<b>34,472</b>	
<b>Females</b>	<b>58,818</b>	
<b>Other factors</b>		
Males	<REDACTED>	Assumption
Females	<REDACTED>	
<b>Total potential TTR-CM patients</b>		
<b>Males</b>	<REDACTED>	Number of patients with HFpEF x % with other factors
<b>Females</b>	<REDACTED>	
<b>Total</b>	<REDACTED>	
<b>Cardiac scintigraphy performed</b>		
Uptake rate of cardiac scintigraphy	<REDACTED>	Assumption
Number of scintigraphies performed	<REDACTED>	Total number of TTR-CM patients x uptake rate of cardiac scintigraphy

See attached spreadsheet

50. Estimate the anticipated uptake of the proposed medical service over the next three years factoring in any constraints in the health system in meeting the needs of the proposed population (such as supply and demand factors) as well as provide commentary on risk of 'leakage' to populations not targeted by the service:

	Year 2	Year 3	Year 4	Source
<b>Population</b>				ABS3222.0 - Population Projections, Australia
<b>Males</b>				
65-74 years	1,161,597	1,170,824	1,186,743	
75-84 years	633,022	675,134	711,247	
≥85 years	206,420	213,921	221,585	
<b>Females</b>				
65-74 years	1,233,309	1,250,878	1,275,672	
75-84 years	713,563	756,541	793,833	
≥85 years	322,841	329,028	335,986	
<b>Prevalence</b>				
<b>Males</b>				
65-74 years	3.6%	3.6%	3.6%	
75-84 years	6.0%	6.0%	6.0%	
≥85 years	8.0%	8.0%	8.0%	
<b>Females</b>				
65-74 years	4.8%	4.8%	4.8%	
75-84 years	7.0%	7.0%	7.0%	
≥85 years	16.8%	16.8%	16.8%	
<b>HF</b>				Population projections x incidence rates
<b>Males</b>				
65-74 years	41,817	42,150	42,723	

<sup>49</sup>Wang N, Hales S, Barin E and Tofter G. Characteristics and outcome for heart failure patients with mid-range ejection fraction. J Cardiovasc Med 2018, 19:297-303

<sup>50</sup> AIHW. Cardiovascular Disease. Australia Facts 2011. Figure 6.1

	Year 2	Year 3	Year 4	Source
75-84 years	37,981	40,508	42,675	
≥85 years	16,514	17,114	17,727	
<b>Total</b>	<b>96,312</b>	<b>99,771</b>	<b>103,124</b>	
<b>Females</b>				
65-74 years	59,199	60,042	61,232	
75-84 years	49,949	52,958	55,568	
≥85 years	54,237	55,277	56,446	
<b>Total</b>	<b>163,386</b>	<b>168,277</b>	<b>173,246</b>	
<b>HFpEF</b>				
HFpEF	37%	37%	37%	Wang 2018 <sup>51</sup>
<b>Males</b>	<b>35,636</b>	<b>36,915</b>	<b>38,156</b>	
<b>Females</b>	<b>60,453</b>	<b>62,262</b>	<b>64,101</b>	
<b>Other factors</b>				
Males	<REDACTED>	<REDACTED>	<REDACTED>	Assumption
Females	<REDACTED>	<REDACTED>	<REDACTED>	
<b>Total potential TTR-CM patients</b>				
<b>Males</b>	<REDACTED>	<REDACTED>	<REDACTED>	Number of patients with HFpEF x % with other factors based on “red flags” for TTR-CM
<b>Females</b>	<REDACTED>	<REDACTED>	<REDACTED>	
<b>Total</b>	<REDACTED>	<REDACTED>	<REDACTED>	
<b>Cardiac scintigraphy performed</b>				
Uptake rate of cardiac scintigraphy	<REDACTED>	<REDACTED>	<REDACTED>	Assumption
Patients brought forward from previous year	<REDACTED>	<REDACTED>	<REDACTED>	Carried forward from previous year
Total TTR-CM patients carried forward to next year	<REDACTED>	<REDACTED>	<REDACTED>	Total number of TTR-CM patients – all patients who received cardiac scintigraphy (all years)
<b>Patients who will receive cardiac scintigraphies per year</b>	<REDACTED>	<REDACTED>	<REDACTED>	Total potential TTR-CM patients ((patients year <sub>x+1</sub> – patients year <sub>x</sub> ) + total TTR-CM patients brought forward from previous year) x uptake rate

See attached spreadsheet.

<sup>51</sup>Wang N, Hales S, Barin E and Tofler G. Characteristics and outcome for heart failure patients with mid-range ejection fraction. J Cardiovasc Med 2018, 19:297–303

## PART 8 – COST INFORMATION

**51. Indicate the likely cost of providing the proposed medical service. Where possible, please provide overall cost and breakdown:**

Cost	Year 1	Year 2	Year 3	Year 4
Average of MBS items listed below	\$514.19	\$514.19	\$514.19	\$514.19
Annual cost	<REDACTED>	<REDACTED>	<REDACTED>	<REDACTED>

**52. Specify how long the proposed medical service typically takes to perform:**

A cannula is inserted which takes approximately 10 minutes. This is followed by scanning during which time the patient may be injected with the radiopharmaceutical which takes 5-15 minutes. This is followed by a break, approximately 3 hours, which depends on the radiopharmaceutical being used and local practice. This is followed by delayed imaging.

**53. If public funding is sought through the MBS, please draft a proposed MBS item descriptor to define the population and medical service usage characteristics that would define eligibility for MBS funding.**

Proposed item descriptors are as follows (V-Z included as placeholders for the item name):

Category 5 – Diagnostic Imaging Service
<p>Item number V</p> <p>Proposed item descriptor: ASSESSMENT OF CARDIAC UPTAKE, RELATIVE TO BONE UPTAKE, FOR THE PURPOSES OF DIAGNOSIS OF TRANSTHYRETIN CARDIAC AMYLOIDOSIS including when undertaken, blood flow, blood pool and repeat imaging on a separate occasion (R)</p> <p>a) using 99mTc-PYP, 99mTC-HDP or 99mTc-DPD, and</p> <p>b) where the patient was referred by a cardiologist or amyloid specialist</p> <p>Fee: \$333.55</p>

**OR**

Category 5 – Diagnostic Imaging Service
<p>Item number W</p> <p>Proposed item descriptor: ASSESSMENT OF CARDIAC UPTAKE, RELATIVE TO BONE UPTAKE, FOR THE PURPOSES OF DIAGNOSIS OF TRANSTHYRETIN CARDIAC AMYLOIDOSIS and single photon emission tomography, including when undertaken, blood flow, blood pool and repeat imaging on a separate occasion (R)</p> <p>a) using 99mTc-PYP, 99mTC-HDP or 99mTc-DPD, and</p> <p>b) where the patient was referred by a cardiologist or amyloid specialist</p> <p>Fee: \$456.20</p>

**OR**

Category 5 – Diagnostic Imaging Service
<p>Item number X</p> <p>Proposed item descriptor: ASSESSMENT OF CARDIAC UPTAKE, RELATIVE TO BONE UPTAKE, FOR THE PURPOSES OF DIAGNOSIS OF TRANSTHYRETIN CARDIAC AMYLOIDOSIS - whole body, with when undertaken, blood flow, blood pool and delayed imaging on a separate occasion (R)</p> <p>a) using 99mTc-PYP, 99mTC-HDP or 99mTc-DPD, and</p> <p>b) where the patient was referred by a cardiologist or amyloid specialist</p> <p>Fee: \$479.80</p>

OR

Category 5 – Diagnostic Imaging Service
<p>Item number Y</p> <p>Proposed item descriptor: ASSESSMENT OF CARDIAC UPTAKE, RELATIVE TO BONE UPTAKE, FOR THE PURPOSES OF DIAGNOSIS OF TRANSTHYRETIN CARDIAC AMYLOIDOSIS - whole body and single photon emission tomography, with, when undertaken, blood flow, blood pool and delayed imaging on a separate occasion (R)</p> <p>a) using 99mTc-PYP, 99mTc-HDP or 99mTc-DPD, and</p> <p>b) where the patient was referred by a cardiologist or amyloid specialist</p> <p>Fee: \$600.70</p>

**AND WITH MBS ITEM Y IN SOME PATIENTS**

Category 5 – Diagnostic Imaging Service
<p>Item number Z</p> <p>Proposed item descriptor: CT scan performed at the same time and covering the same body area as single photon emission tomography for the purpose of diagnosis of transthyretin cardiac amyloidosis where no separate diagnostic CT report is issued and only in association with item Y (R)</p> <p>where the patient was referred by a cardiologist or amyloid specialist</p> <p>Fee: \$100.00</p>

Fees of the MBS items on which these proposed items are based, namely MBS items 61445, 61449, 61421, 61425 and 61505, have been used as Dr <REDACTED> indicated that the staffing and equipment required, interviewing and assessment of the patient, injection of radiopharmaceutical, time delay and time/nature of scanning required for ATTR scans and for standard bone scans are essentially identical to the original bone studies.