



**Australian Government**

**Department of Health**

# **RATIFIED PICO**

## **Application 1605:**

**Transcatheter delivery of a dual-filter cerebral embolic protection (CEP) system during transcatheter aortic valve implantation (TAVI)**

*Summary of PICO/PPICO criteria to define the question(s) to be addressed in an Assessment Report to the Medical Services Advisory Committee (MSAC)*

<b>Component</b>	<b>Description</b>
Patients	Patients with symptomatic severe aortic stenosis who meet MBS eligibility criteria for transcatheter aortic valve implantation (TAVI)
Intervention	Percutaneous transcatheter dual-filter cerebral embolic protection (CEP) system
Comparator	TAVI procedure without the use of a dual-filter CEP system (i.e. standard of care, SoC).
Outcomes	<p>Safety Outcomes:</p> <ul style="list-style-type: none"> <li>• Procedural complications related to the device</li> <li>• Acute kidney injury</li> <li>• Major Vascular complication (i.e. radial/brachial, femoral arteries)</li> </ul> <p>Clinical Effectiveness Outcomes:</p> <ul style="list-style-type: none"> <li>• Mortality</li> <li>• Reduction in clinical stroke</li> <li>• Reduction in transient ischaemic attack</li> <li>• Neurocognitive dysfunction post-procedure</li> <li>• Peri-procedural ischaemic stroke</li> <li>• New lesion volume detected by magnetic resonance imaging (MRI)</li> <li>• New cerebral lesions detected by MRI</li> <li>• Health-related quality of life</li> </ul> <p>Cost-effectiveness:</p> <ul style="list-style-type: none"> <li>• Resource utilisation (surgical costs, follow-up imaging [computed tomography [CT], MRI], rehabilitation, pain management medication, length of hospital stay in Australia)</li> <li>• Cost per quality-adjusted life year</li> </ul> <p>Total Australian Government healthcare costs:</p> <ul style="list-style-type: none"> <li>• Total cost to the Medicare Benefits Schedule (MBS)</li> <li>• Total cost to Government health budgets</li> </ul>

## POPULATION

*PASC confirmed the proposed population is “patients with symptomatic severe aortic stenosis who meet MBS eligibility criteria for transcatheter aortic valve implantation (TAVI)”. PASC advised that this would ‘future-proof’ the MBS item descriptor.*

*PASC advised that the evidence base will need to evaluate both high-risk and intermediate-risk TAVI populations.*

*PASC noted the applicant’s request that eligibility for CEP not be based on patient risk, and be expanded to include intermediate-risk patients (together with the originally-requested high-risk patients). PASC advised that the assessment report will need to demonstrate sufficient rationale for this, including clinical evidence for both patient groups.*

The proposed medical service is intended to be used as an adjunct during the transcatheter aortic valve implantation (TAVI) procedure (MBS item 38495) to capture and remove debris dislodged while undergoing TAVI. The TAVI procedure is an alternative to traditional surgical aortic valve replacement (open heart surgery), being a minimally invasive procedure that replaces the aortic valve of patients with severe symptomatic aortic stenosis (a narrowing or obstruction of the main artery exiting the heart). This narrowing is typically caused by the build-up of plaque, which is made up of hardened substances found in the blood (such as fat, cholesterol, and calcium). During the TAVI procedure, plaque and other debris can break away from the artery or valve and float loosely in the bloodstream, with the emboli travelling to smaller arteries in the brain or other vital organs. Here, the embolic debris blocks the flow of blood and prevents the supply of oxygen, causing ischaemia, which can result in brain damage or death.

The dual-filter CEP system is used as an adjunctive procedure to TAVI and is designed to reduce the risk of peri-operative embolic ischaemic strokes.

Patients who would be eligible for the proposed medical service would therefore be patients who are undergoing the TAVI procedure; that is, patients with symptomatic aortic stenosis deemed high risk for surgical aortic valve replacement or non-operable and who meet MBS eligibility criteria for TAVI (MBS item 38495). The proposed MBS item descriptor does not restrict use of the dual-filter CEP system to the MBS eligible population for TAVI.

Further eligibility for the dual-filter CEP system is largely dependent on the patient’s aortic arch anatomy fitting the size requirements for the CEP system (Van Mieghem et al. 2016), as noted below:

- the brachiocephalic trunk should range between 9 and 15 mm; and
- the left common carotid artery should range between 6.5 and 10 mm; and
- be without excessive tortuosity, or not have > 70 % obstructive atherosclerotic disease.

Computed tomography (CT) scans would be required to determine the size of the aortic annulus, the access vessels, the brachiocephalic trunk, and the left common carotid artery. The applicant quoted a key opinion leader estimate that approximately 90% of the patients who are eligible for TAVI would be eligible for the CEP system. According to the Medicare Benefits Schedule, there were 1,300 requested items processed from July 2018 to June 2019 for TAVI (MBS item 38495), an increase from 451 items processed from July 2017 to June 2018. MBS rebates for the medical assessment of a patient's suitability for TAVI (a TAVI Case Conference) are also available and are listed as items 6080 and 6081.

Prevalence of aortic stenosis in Australia has remained close to 5.4% during the 2015 to 2018 period. The applicant estimated that prevalence of the disease will gradually increase by 0.1% each year from 2019. The prevalence of symptomatic severe aortic stenosis in Australia has been estimated in previous MSAC applications (MSAC applications 1361, 1361.1, 1361.2 and 1552) to be 2.6% in a population aged 75 or over (Osnabrugge et al. 2013). Later studies have estimated there are approximately 66,557 Australians aged  $\geq 55$  years living with severe aortic stenosis, with approximately 7,425 of these eligible for aortic valve replacement using TAVI (De Sciscio, Brubert, and De Sciscio 2015), and an estimated prevalence of symptomatic severe AS of 0.4% in patients aged 60 to 74 years and 1.9% in patients aged  $\geq 75$  years (De Sciscio et al. 2017).

### **Rationale**

Stroke is one of Australia's biggest killers and a leading cause of disability (AIHW 2018); 65% of stroke survivors suffer a disability which impedes their ability to carry out daily living activities unassisted (Deloitte Access Economics 2013).

Many endovascular procedures associated with structural interventions are known to place patients at risk of ischaemic stroke. In this regard, the potential for stroke is a potential deterrent that may lead a physician to choose to not perform a TAVI procedure on a patient with severe symptomatic aortic stenosis. The TAVI procedure alone carries an inherent risk of stroke, with large registries reporting the incidence of clinical stroke 30-days after the TAVI procedure varying between 1.7% and 4.8% (Grabert, Lange, and Bleiziffer 2016; Eltchaninoff et al. 2011; Leon et al. 2010; Nuis et al. 2012; Tamburino et al. 2011). There is also a high incidence of clinically silent ischaemic cerebral perfusion or microinfarcts after TAVI (Hynes and Rodes-Cabau 2012; Muscente and De Caterina 2019), potentially leading to cognitive decline and/or increased risk of future clinical stroke and mortality.

## **INTERVENTION**

*PASC confirmed the proposed intervention, noting it is for any TAVI device (i.e. CEP is agnostic to TAVI valve type).*

*At the applicant's request, PASC agreed the intervention should be "transcatheter", rather than "transradial". This is because arteries other than the radial artery are occasionally used.*

*PASC noted that, while CEP could be used in other procedures (e.g. the TGA indication is not specific to TAVI), in this application, it is being restricted to TAVI, given that is where most evidence exists. This means the same accreditation requirements for operators and institutions will apply for this procedure as for TAVI.*

*PASC queried whether TAVI should ever be performed without CEP. The applicant stated there are about 10% of patients for whom CEP is not suitable (due to anatomical or other clinical considerations), and practitioners can clinically judge if CEP should be performed.*

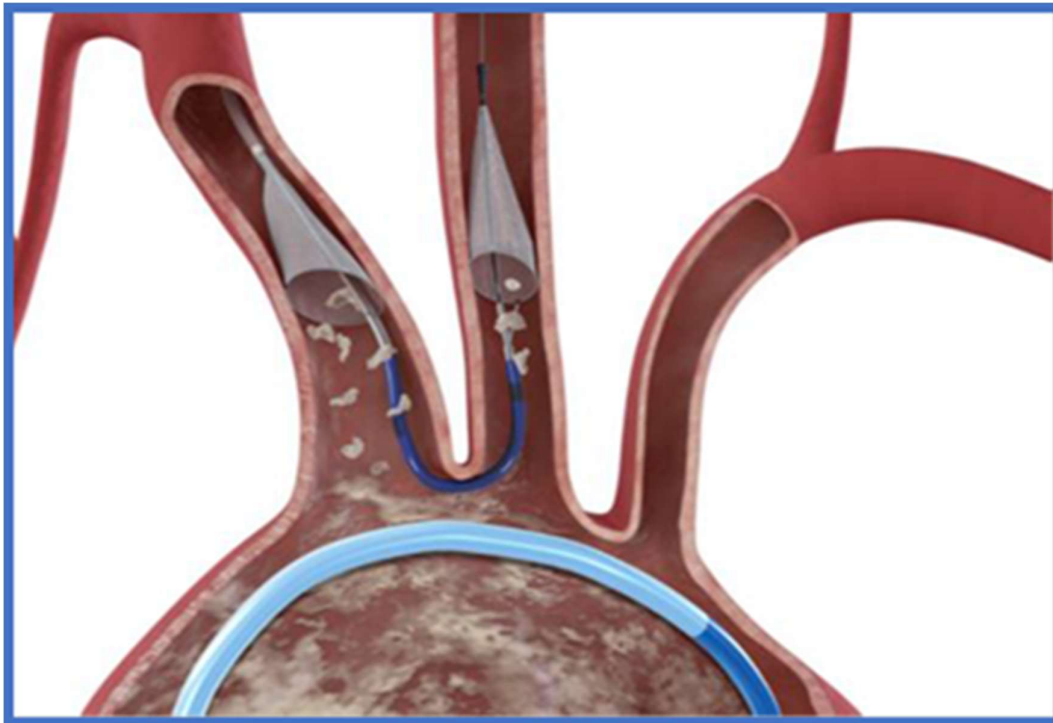
The proposed medical service is a percutaneous delivered dual-filter cerebral embolic protection (CEP) device delivered during transcatheter aortic valve implantation (TAVI) for the reduction of post-operative embolic ischaemic strokes. Use of the dual-filter CEP system is to be used in addition to the TAVI procedure (MBS item 38495) and is not intended to substitute any current services.

Details of key components and clinical steps involved in delivery of the intervention specifically refer to use of the Sentinel™ Cerebral Protection System (Claret Medical™); [Sentinel™ CPS] (ARTG listing number: 319101). The TGA-approved purpose indicates it is used as an embolic protection device, to capture and remove embolic material (thrombus/debris) that may enter the cerebral vascular system during endovascular procedures. Diameters of arteries at the sites of filter placement should be measured, and the filters sized to the proximal and distal target vessels. The dual-filter CEP system (Sentinel) is listed on the Prostheses List (BS364), with the benefit for the CEP filters being \$1,955.

The dual-filter CEP system utilises an embolic filter delivered to the brachiocephalic artery (proximal filter), and a second embolic filter delivered to the left common carotid artery (distal filter) (Figure 1). It is noted the dual-filter CEP system does not protect the left subclavian artery (and therefore cerebral circulation supplied by the left vertebral artery) from emboli, and there have been studies investigating the effect of additional protection of arteries supplying the brain. (Van Gils et al. 2018) At completion of the procedure, the filters and debris are recaptured into the catheter and removed from the patient. The dual-filter CEP system consists of a 6 French catheter, with deployable proximal and distal filters, an articulating sheath and an integral handle assembly. The articulating sheath tip, proximal sheath tip, proximal filter hoop, distal filter hoop and distal filter tip are radiopaque, to enable visualisation during use.

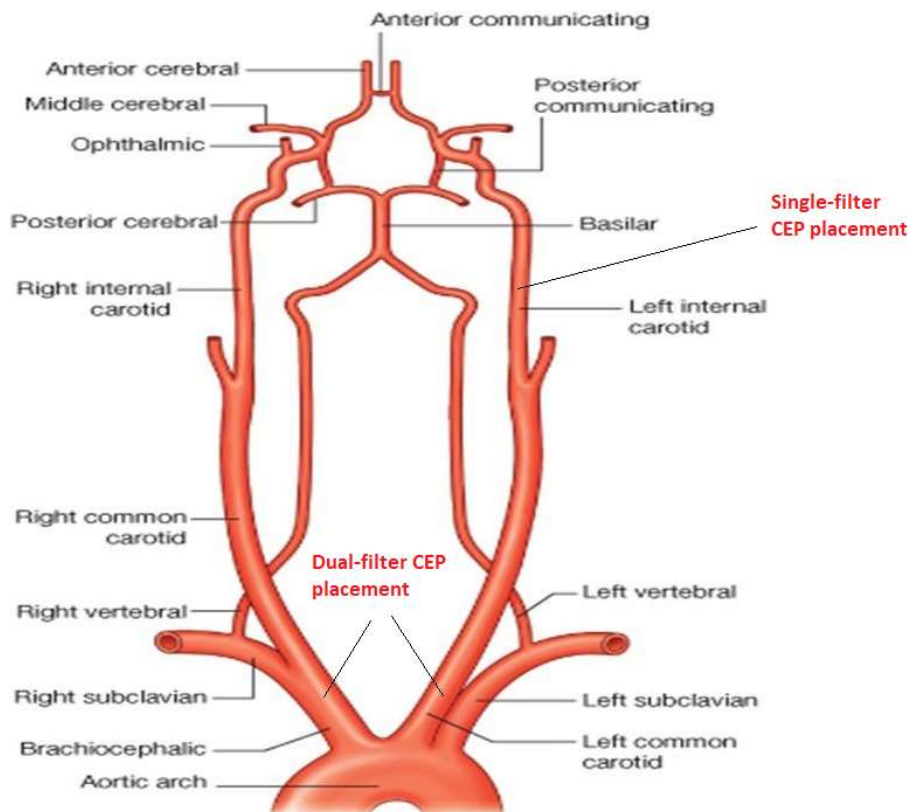
None of the filters currently listed on the Prostheses List are specifically indicated, or used, as part of the TAVI procedure, and are not comparable to the dual-filter CEP as they are single filter devices and are sized for the internal carotid artery (i.e. are sized too small to be used in either the left common carotid, or the brachiocephalic artery, or present a double-occlusion balloon system for use in small diameter carotid arteries) (refer to Figure 2). Furthermore, they are not able to protect the right vertebral artery, which accounts for 10% of the cerebral blood flow.

Figure 1: Illustration of Sentinel CEP system placement



Source: Figure 1, p 14 of 1605 Application Form

Figure 2: Vascular neuroanatomy indicating placement of dual-filter CEP vs majority of single-filter CEP placement



A summary of the steps involved in the procedural delivery and deployment of the dual-filter CEP system, are presented in Table 1; the steps for the retrieval are presented in Table 2.

**Table 1: Stepped procedure for delivery and deployment of the dual-filter CEP system**

Step	Procedure
1.	Loosen the Rear Handle Lock.
2.	Recover the Distal Filter using one of the following two methods: a) Full Enclosure Recovery: Gently withdraw the Distal Filter Slider relative to the Rear Handle until the radiopaque Distal Filter tip is flush with the Radiopaque Articulating Sheath Tip Marker as visualised on fluoroscopy. Tighten the Rear Handle Lock. If resistance is felt during Distal Filter recovery, or if it is believed that the Distal Filter is excessively full, follow the Partial Enclosure Recovery method detailed below. b) Partial Enclosure Recovery: Gently withdraw the Distal Filter Slider relative to the Rear Handle until the Distal Filter Radiopaque Hoop is collapsed inside the Articulating Sheath tip as visualised on fluoroscopy. Tighten the Rear Handle Lock.
3.	Loosen the Front Handle Lock and withdraw the Articulating Sheath tip from the left common carotid artery by manipulating, straightening, rotating, and advancing or withdrawing the Rear Handle and rotating the Articulation Knob until the Articulating Sheath tip is straight and is within the aorta.
4.	Advance the Articulating Sheath completely by advancing the Rear Handle until the Articulation Knob contacts the Front Handle Lock to prevent interference with the Proximal Sheath or Proximal Filter during Proximal Filter retrieval. Tighten the Front Handle Lock.
5.	Re-sheath the Proximal Filter by holding the Front Handle in a stationary position and slowly advancing the Proximal Filter Slider until the Proximal Sheath Radiopaque Marker meets the Articulating Sheath as visualised on fluoroscopy. Minimise retracting or advancing the Front Handle during this step. Vessel damage may occur, or debris may be lost should the Proximal Filter be moved when in the deployed state.
6.	Advance the guidewire prior to withdrawal of the dual-filter CEP system. Withdraw the catheter system while using fluoroscopy.
7.	Deploy the Proximal Filter by holding the Front Handle in a fixed position and slowly retracting the Proximal Filter Slider fully.
8.	Confirm proper Proximal Filter position using fluoroscopy. The Proximal Filter should be positioned in the brachiocephalic artery to prevent any debris from reaching the right carotid artery.
9.	If the filter position is not optimal, the filter may be retrieved and repositioned up to two times. This may be done by holding the Front Handle in a stationary position and advancing the Proximal Filter Slider until the Proximal Filter is re-sheathed. The Proximal Filter may then be repositioned by advancing or retracting the catheter until optimal positioning is achieved. Finally the Proximal Filter is redeployed by retracting the Proximal Filter Slider while holding the Front Handle in a fixed position.
10.	Confirm filter-to-vessel wall apposition using fluoroscopy and ensure that the Proximal Filter and Proximal Sheath do not move after placement.
11.	Withdraw the guidewire until the tip is located just within the distal tip of Sentinel catheter.
12.	Loosen the Front Handle Lock to facilitate positioning of the Articulating Sheath.
13.	Position the Articulating Sheath by manipulating the Rear Handle relative to the Front Handle in order to position the catheter tip. Rotate the Articulation Knob on the Rear Handle in the direction of the arrows in order to deflect the tip of the Articulating Sheath as necessary towards the left common carotid artery ostium.
14.	Advance the 0.014" guidewire beyond the distal tip of the Articulating Sheath in order to place the guidewire in the left common carotid artery.

Step	Procedure
15.	Position the Articulating Sheath so that the curvature matches the brachiocephalic artery – Aorta – Left Common Carotid Artery junction and is pulled up to the carina between the two vessels.
16.	Secure the position of the Articulating Sheath by tightening the Front Handle Lock.
17.	Loosen the Rear Handle Lock and advance the Distal Filter under fluoroscopy by pushing the Distal Filter Slider forward until the Distal Filter frame is fully expanded and apposed to the vessel wall. The Distal Filter should be positioned just beyond the Articulating Sheath tip and movement should be minimised once it is fully expanded in the vessel.
18.	Confirm filter-to-vessel wall apposition of the Distal Filter using fluoroscopy.
19.	Tighten the Rear Handle Lock.
20.	Cover the exposed portion of the dual-filter CEP system with a drape to prevent movement during subsequent endovascular procedures.

Source: pp 14-15 of 1605 Application Form

**Table 2: Stepped procedure for removal of the dual-filter CEP system**

Step	Procedure
1.	Loosen the Rear Handle Lock.
2.	Recover the Distal Filter using one of the following two methods: <ul style="list-style-type: none"> <li>a) Full Enclosure Recovery: Gently withdraw the Distal Filter Slider relative to the Rear Handle until the radiopaque Distal Filter tip is flush with the Radiopaque Articulating Sheath Tip Marker as visualised on fluoroscopy. Tighten the Rear Handle Lock. If resistance is felt during Distal Filter recovery, or if it is believed that the Distal Filter is excessively full, follow the Partial Enclosure Recovery method detailed below.</li> <li>b) Partial Enclosure Recovery: Gently withdraw the Distal Filter Slider relative to the Rear Handle until the Distal Filter Radiopaque Hoop is collapsed inside the Articulating Sheath tip as visualised on fluoroscopy. Tighten the Rear Handle Lock.</li> </ul>
3.	Loosen the Front Handle Lock and withdraw the Articulating Sheath tip from the left common carotid artery by manipulating, straightening, rotating, and advancing or withdrawing the Rear Handle and rotating the Articulation Knob until the Articulating Sheath tip is straight and is within the aorta.
4.	Advance the Articulating Sheath completely by advancing the Rear Handle until the Articulation Knob contacts the Front Handle Lock to prevent interference with the Proximal Sheath or Proximal Filter during Proximal Filter retrieval. Tighten the Front Handle Lock.
5.	Re-sheath the Proximal Filter by holding the Front Handle in a stationary position and slowly advancing the Proximal Filter Slider until the Proximal Sheath Radiopaque Marker meets the Articulating Sheath as visualised on fluoroscopy. Minimise retracting or advancing the Front Handle during this step. Vessel damage may occur or debris may be lost should the Proximal Filter be moved when in the deployed state.
6.	Advance the guidewire prior to withdrawal of the dual-filter CEP system. Withdraw the catheter system while using fluoroscopy.

Source: pp 15 of 1605 Application Form

### **Provider type**

The dual-filter CEP system is to be used in conjunction with TAVI (MBS item 38495), which states:

*TAVI, for the treatment of symptomatic severe aortic stenosis, performed via transfemoral delivery, unless transfemoral delivery is contraindicated or not feasible, in a TAVI Hospital on a TAVI Patient by a TAVI Practitioner – includes all intraoperative diagnostic imaging that the TAVI Practitioner performs upon the TAVI Patient.*





The comparator nominated by the applicant was the TAVI procedure without the use of a dual-filter CEP system (i.e. standard of care, SoC).

The management for a patient who receives the proposed medical service would be the same as a patient who receives the TAVI procedure without the dual-filter CEP system. After the procedure, the patient remains in hospital for approximately 5 days for post-procedure observation. Should the patient display signs or symptoms of a stroke within 72 hours of the procedure, a CT or MRI is scheduled to diagnose if a peri-procedural stroke has occurred. The strokes prevented by using the dual-filter CEP system are captured within the first 72 hours post-procedure. Strokes occurring  $\geq 7$  days post-procedure are considered to not be procedure-related. A patient who displays no signs or symptoms of a stroke during the hospital stay can be discharge with no imaging required. A high proportion of patients undergoing TAVI could experience silent ischaemic strokes. These would potentially go unnoticed and would only be picked up on a scan which is not routinely performed.

Embolic deflection devices have been investigated for protection against emboli entering the brachiocephalic artery and left common carotid artery by creating a barrier and deflecting the emboli. No deflection devices are currently listed on the ARTG. In comparison to the dual-filter CEP system, these deflection devices do not capture and remove embolic material, which can lead to this material causing potential harm elsewhere in the circulatory system. Given the mechanism of action of the deflection device is to deflect the debris, rather than filter and capture, the applicant considered that the deflection device is not an equivalent to the dual filter CEP device and as such does not form part of the intervention in this assessment. Moreover, given the use of deflection devices does not form part of standard care of patients in Australia undergoing TAVI coupled with no deflector devices registered for use in Australia, a deflector device is not an appropriate comparator to the dual-filter CEP in this Application.

## OUTCOMES

*PASC confirmed the proposed outcomes, but agreed with the applicant's response to the draft PICO that 'acute kidney injury' and 'major vascular complication (i.e. radial/brachial, femoral arteries)' should be moved from clinical outcomes to safety outcomes. However, PASC queried how CEP affected acute kidney injury, given CEP doesn't protect the descending aorta territory.*

An application for percutaneous transcatheter delivery of a dual-filter CEP system was considered by PLAC at its meeting of 16 May 2019, with PLAC members seeking further advice on whether use of the CEP system (as an adjunctive) delivers improvements in outcomes of the TAVI procedure.

### **Patient-relevant outcomes**

Safety outcomes include any adverse events related to the proposed service and the nominated comparator, and could include:

- Procedural complications related to the device
- Acute kidney injury
- Major vascular complication (i.e. radial/brachial, femoral arteries)

Effectiveness outcomes related to the proposed service and appropriate comparator are as follows:

- Mortality
- Reduction in clinical stroke
- Reduction in transient ischaemic attack
- Neurocognitive dysfunction post-procedure
- Peri-procedural ischaemic stroke
- New lesion volume detected by MRI
- New cerebral lesions detected by MRI
- Health-related quality of life

#### **Healthcare system outcomes**

- Hospital length of stay
- Resource utilisation

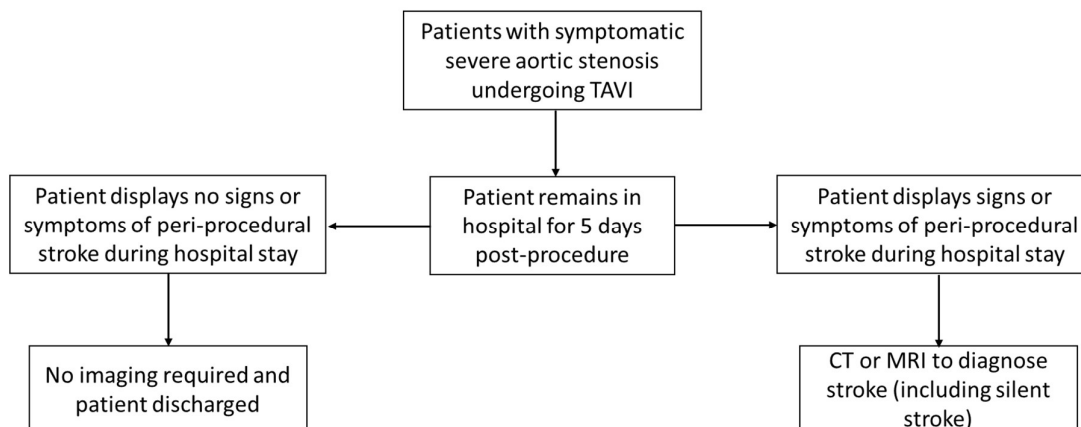
## **CLINICAL MANAGEMENT ALGORITHMS**

*PASC confirmed the proposed clinical management algorithm.*

### **Current clinical management algorithm for identified population**

The current clinical management as proposed in the application is illustrated in Figure 3 below. Here, patients with severe aortic stenosis undergoing the TAVI procedure remain in hospital for observation for five days post-procedure. Patients are assessed for signs and symptoms of peri-procedural stroke, and if stroke is suspected at any time during the inpatient stay, confirmation of a stroke is conducted within hospital. If the patient does not display signs or symptoms of stroke during the inpatient stay, they are discharged after the five-day period.

**Figure 3: Current clinical management algorithm**



Source: Figure 4, p26 of Application Form

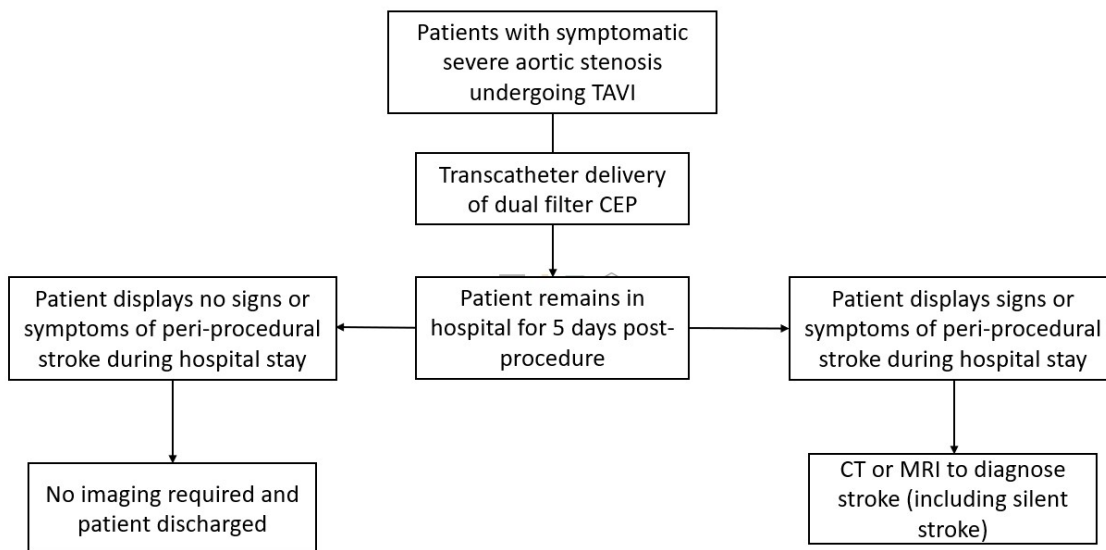
Abbreviations: CEP, cerebral embolic protection; CT, computer tomography; MRI, magnetic resonance imaging; TAVI, transcatheter aortic valve implantation

*Note, patients undergoing TAVI meeting the MBS eligibility criteria for TAVI procedure (e.g. unacceptably high risk for surgical aortic valve replacement)*

## Proposed clinical management algorithm for identified population

The only proposed change to the current clinical management algorithm in Figure 3 is the use of the dual-filter CEP system prior to the TAVI procedure, as illustrated in Figure 4.

Figure 4: Proposed clinical management algorithm



Source: Figure 4, p26 of Application Form

Abbreviations: CEP, cerebral embolic protection; CT, computer tomography; MRI, magnetic resonance imaging; TAVI, transcatheter aortic valve implantation

Note, patients undergoing TAVI meeting the MBS eligibility criteria for TAVI procedure

## PROPOSED ECONOMIC EVALUATION

PASC confirmed a cost-utility model is appropriate. PASC noted the price of **\$REDACTED** will be used in the assessment report (relative to the \$1,995 benefit for arterial embolic protection devices currently on the Prostheses List). Price justification will be needed during the evaluation.

PASC noted an application (1603) was currently underway for TAVI in patients at intermediate risk for surgery:

- PASC advised the economic analyses might need to look separately at high-risk and intermediate-risk patients, if clinical and cost outcomes were different across these two patient subgroups
- PASC also advised that financial implications should be looked at separately for high-risk and intermediate-risk patients, in case the other application (1603) is funded, as this will lead to a larger group of eligible patients

The overall clinical claim is that the proposed medical service (transcatheter delivery of a dual-filter CEP system during TAVI) is superior in terms of comparative effectiveness and superior in terms of comparative safety when compared to the TAVI procedure without the delivery of a dual-filter CEP system.

This is based on several prospective observational studies and pooled analyses that reported the dual-filter CEP system to be associated with significantly fewer neurological events 24 hours post-procedure (Kroon et al. 2019; Seeger et al. 2019) and a reduction in stroke within 7-days post-procedure (Seeger et al. 2017). Results from randomised controlled trial (RCTs) are somewhat mixed however, with one RCT (Kapadia et al. 2017) concluding that there were no statistically significant differences between TAVI with or without the dual-filter CEP system in regards to major adverse cardiovascular and cerebral events (MACCE) or new lesion volumes, however Van Mieghem (2016) and Haussig (2016) both found that the number of new lesions and overall volume of lesions reduced with the use of a dual-filter CEP system (Haussig et al. 2016; Van Mieghem et al. 2016).

Based on the assumption that clinical superiority will be claimed a cost-utility model is appropriate, providing an incremental cost per quality-adjusted life year (QALY) gained.

### **PROPOSED MBS ITEM DESCRIPTOR/S AND MBS FEES (if relevant)**

*PASC agreed with the applicant that the term ‘transradial’ should be replaced with ‘transcatheter’, both in the item descriptor and throughout the assessment documents. This is to capture alternative routes that may be needed in some patients. This is actioned in this PICO.*

*PASC noted the proposed MBS fee is based on increased procedure time (compared to TAVI without CEP). The applicant advertises a ‘deployment’ time of four minutes, but it is understood there are some required preparations prior to deployment, so this will need to be clearly justified in the assessment report.*

*PASC confirmed the proposed MBS item is subject to the multiple operation rule in Section T8 of the MBS, which reduces the fee payable by 50%.*

The proposed MBS item descriptor is detailed below.

<b>Category 3 – Therapeutic Procedures</b>
<p>Percutaneous transcatheter delivery of dual-filter cerebral embolic protection (CEP) system during transcatheter aortic valve implantation (TAVI), for the reduction of post-operative embolic ischaemic strokes</p> <p><b>MBS Fee: \$277.92</b></p>

Source: p24 of Application Form

The proposed MBS fee for this item is based on additional procedure time compared with a TAVI procedure without use of a dual-filter CEP system, estimated to be 81 minutes versus 68 minutes (Kapadia et al. 2017). Use of a dual-filter CEP system is estimated to increase procedure duration by 13 minutes, equivalent to 19.1% of time taken for TAVI without use of the dual-filter CEP system. Therefore, an additional MBS fee of \$277.92 is proposed for insertion of the dual-filter CEP system, representing 19.1% of the current TAVI fee (MBS item 38495 = \$1,455.10).

Note: The dual-filter CEP system (device) cost is **\$REDACTED** (in addition to current TAVI devices), where TAVI devices are currently listed on the Prostheses List for \$22,932 (July 2019). As such, the dual-filter CEP system adjunct to TAVI procedures is estimated to result in total device costs of **\$REDACTED**.

## CONSULTATION FEEDBACK

*PASC noted consultation feedback from one nurse practitioner, who was supportive of the proposed service.*

## NEXT STEPS

*Upon ratification of PICO 1605, the application can PROCEED to the pre-Evaluation Sub-Committee (ESC) stage.*

*The applicant has elected to prepare its own ADAR (applicant-developed assessment report).*

## References

- De Sciscio, P., J. Brubert, and M. De Sciscio. 2015. 'Aortic stenosis in Australia: disease prevalence and patient eligibility for aortic valve replacement', *Heart, Lung and Circulation*, 24: S409.
- De Sciscio, P., J. Brubert, M. De Sciscio, M. Serrani, J. Stasiak, and G. D. Moggridge. 2017. 'Quantifying the Shift Toward Transcatheter Aortic Valve Replacement in Low-Risk Patients: A Meta-Analysis', *Circ Cardiovasc Qual Outcomes*, 10.
- Eltchaninoff, H., A. Prat, M. Gilard, A. Leguerrier, D. Blanchard, G. Fournial, B. Lung, P. Donzeau-Gouge, C. Tribouilloy, J. L. Debrux, A. Pavie, P. Gueret, and France Registry Investigators. 2011. 'Transcatheter aortic valve implantation: early results of the FRANCE (FRench Aortic National CoreValve and Edwards) registry', *Eur Heart J*, 32: 191-7.
- Grabert, S., R. Lange, and S. Bleiziffer. 2016. 'Incidence and causes of silent and symptomatic stroke following surgical and transcatheter aortic valve replacement: a comprehensive review', *Interact Cardiovasc Thorac Surg*, 23: 469-76.
- Haussig, S., N. Mangner, M. G. Dwyer, L. Lehmkuhl, C. Lucke, F. Woitek, D. M. Holzhey, F. W. Mohr, M. Gutberlet, R. Zivadinov, G. Schuler, and A. Linke. 2016. 'Effect of a Cerebral Protection Device on Brain Lesions Following Transcatheter Aortic Valve Implantation in Patients With Severe Aortic Stenosis: The CLEAN-TAVI Randomized Clinical Trial', *JAMA*, 316: 592-601.
- Hynes, B. G., and J. Rodes-Cabau. 2012. 'Transcatheter aortic valve implantation and cerebrovascular events: the current state of the art', *Ann N Y Acad Sci*, 1254: 151-63.
- Kapadia, S. R., S. Kodali, R. Makkar, R. Mehran, R. M. Lazar, R. Zivadinov, M. G. Dwyer, H. Jilaihawi, R. Virmani, S. Anwaruddin, V. H. Thourani, T. Nazif, N. Mangner, F. Woitek, A. Krishnaswamy, S. Mick, T. Chakravarty, M. Nakamura, J. M. McCabe, L. Satler, A. Zajarias, W. Y. Szeto, L. Svensson, M. C. Alu, R. M. White, C. Kraemer, A. Parhizgar, M. B. Leon, A. Linke, and Sentinel Trial Investigators. 2017. 'Protection Against Cerebral Embolism During Transcatheter Aortic Valve Replacement', *J Am Coll Cardiol*, 69: 367-77.
- Kroon, H. G., H. W. van der Werf, S. E. Hoeks, L. van Gils, F. R. van den Berge, N. El Faquir, Z. Rahhab, J. Daemen, J. Poelman, R. A. J. Schurer, A. van den Heuvel, P. de Jaegere, P. van der Harst, and N. M. Van Mieghem. 2019. 'Early Clinical Impact of Cerebral Embolic Protection in Patients Undergoing Transcatheter Aortic Valve Replacement', *Circ Cardiovasc Interv*, 12: e007605.
- Leon, M. B., C. R. Smith, M. Mack, D. C. Miller, J. W. Moses, L. G. Svensson, E. M. Tuzcu, J. G. Webb, G. P. Fontana, R. R. Makkar, D. L. Brown, P. C. Block, R. A. Guyton, A. D. Pichard, J. E. Bavaria, H. C. Herrmann, P. S. Douglas, J. L. Petersen, J. J. Akin, W. N. Anderson, D. Wang, S. Pocock, and Partner Trial Investigators. 2010. 'Transcatheter aortic-valve implantation for aortic stenosis in patients who cannot undergo surgery', *N Engl J Med*, 363: 1597-607.
- Muscente, Francesca, and Raffaele De Caterina. 2019. 'Risk of stroke after transcatheter aortic valve implant: the role of the new oral anticoagulants', *European Heart Journal Supplements*, 21: B50-B51.
- Nuis, R. J., N. M. Van Mieghem, C. J. Schultz, A. Moelker, R. M. van der Boon, R. J. van Geuns, A. van der Lugt, P. W. Serruys, J. Rodes-Cabau, R. T. van Domburg, P. J. Koudstaal, and P. P. de Jaegere. 2012. 'Frequency and causes of stroke during or after transcatheter aortic valve implantation', *Am J Cardiol*, 109: 1637-43.
- Osnabrugge, R. L., D. Mylotte, S. J. Head, N. M. Van Mieghem, V. T. Nkomo, C. M. LeReun, A. J. Bogers, N. Piazza, and A. P. Kappetein. 2013. 'Aortic stenosis in the elderly: disease prevalence and number of candidates for transcatheter aortic valve replacement: a meta-analysis and modeling study', *J Am Coll Cardiol*, 62: 1002-12.
- Seeger, J., B. Gonska, M. Otto, W. Rottbauer, and J. Wohrle. 2017. 'Cerebral Embolic Protection During Transcatheter Aortic Valve Replacement Significantly Reduces Death and Stroke Compared With Unprotected Procedures', *JACC Cardiovasc Interv*, 10: 2297-303.
- Seeger, J., S. R. Kapadia, S. Kodali, A. Linke, J. Wohrle, S. Haussig, R. Makkar, R. Mehran, W. Rottbauer, and M. Leon. 2019. 'Rate of peri-procedural stroke observed with cerebral embolic protection during transcatheter aortic valve replacement: a patient-level propensity-matched analysis', *Eur Heart J*, 40: 1334-40.

- Tamburino, C., D. Capodanno, A. Ramondo, A. S. Petronio, F. Etori, G. Santoro, S. Klugmann, F. Bedogni, F. Maisano, A. Marzocchi, A. Poli, D. Antonucci, M. Napodano, M. De Carlo, C. Fiorina, and G. P. Ussia. 2011. 'Incidence and predictors of early and late mortality after transcatheter aortic valve implantation in 663 patients with severe aortic stenosis', *Circulation*, 123: 299-308.
- Van Gils, Lennart, Herbert Kroon, Joost Daemen, Claire Ren, Anne-Marie Maugenest, Marguerite Schipper, Peter P De Jaegere, and Nicolas M Van Mieghem. 2018. 'Complete filter-based cerebral embolic protection with transcatheter aortic valve replacement', *Catheterization and Cardiovascular Interventions*, 91: 790-97.
- Van Mieghem, N. M., L. van Gils, H. Ahmad, F. van Kesteren, H. W. van der Werf, G. Brueren, M. Storm, M. Lenzen, J. Daemen, A. F. van den Heuvel, P. Tonino, J. Baan, P. J. Koudstaal, M. E. Schipper, A. van der Lugt, and P. P. de Jaegere. 2016. 'Filter-based cerebral embolic protection with transcatheter aortic valve implantation: the randomised MISTRAL-C trial', *EuroIntervention*, 12: 499-507.